US Evaluation of Twin Pregnancies: Importance of Chorionicity and Amnionicity

Priyanka Jha, MBBS[1], Tara Morgan, MD[1], Anne Kennedy, MB BCh[2]

1. Department of Radiology and Biomedical Imaging, University of California San Francisco
2. Department of Radiology and Imaging Sciences, University of Utah Medical Center

Disclosures:
Dr. Kennedy receives royalties from Elsevier

RadioGraphics
Exhibit from the RSNA Annual Meeting

Understanding Chorionicity and Amnionicty

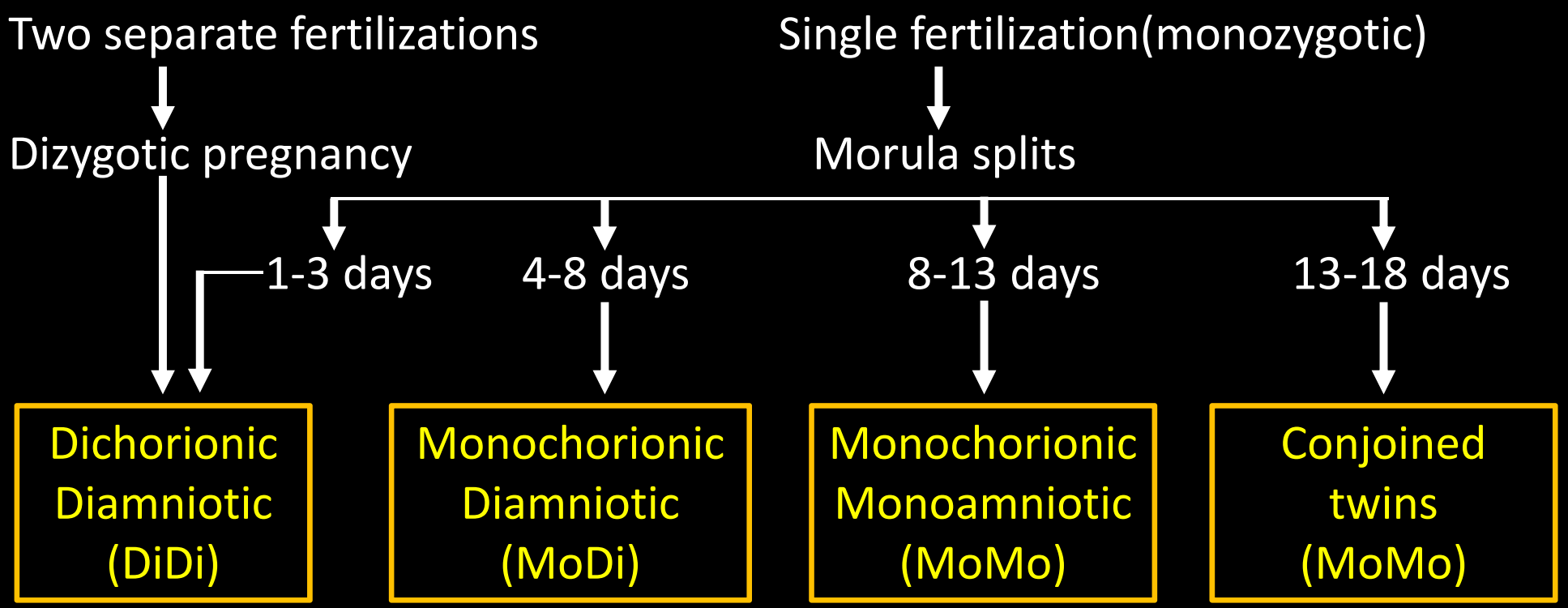

Ultrasound in 1st trimester (7-9 weeks) can be up to 98% accurate in predicting chorionicity.
Amnionicity can be challenging due to non-visualization of membranes. Repeat US, if necessary.

Why are Chorionicity and Amnionicity Important?

- Monochorionic (MC) twins account for 20% of twin pregnancies but *30% of all-cause pregnancy related complications*.
- Single shared placenta hemodynamically connects two fetuses
- Rate of stillbirth in monochorionic compared to dichorionic twins:

  44.4 versus 12.2 per 1,000 births (relative risk: 3.6)
- Rate of neonatal mortality in monochorionic compared to dichorionic twins:

  32.4 versus 21.4 per 1,000 births (relative risk: 1.5)
- Twin pregnancies have a *higher maternal risk* of preterm labor, hypertensive disorders, diabetes, preterm labor, and premature rupture of membranes.
- Monochorionic diamniotic twins have unique complications including *unequal placental sharing, twin-twin transfusion syndrome, twin anemia-polycythemia sequence, and twin reversed arterial perfusion syndrome*.
- Monochorionic monoamniotic pregnancies have unique complications of *conjoined twins, cord entanglement* and higher rates of intrauterine demise.
- The later the age at which the morula splits, the higher the risk of congenital malformations.

Chorionicity and Amnionicity in the First Trimester

Number of Gestational Sacs = Chorionicity!

Number of Yolk Sacs = Amnionicity

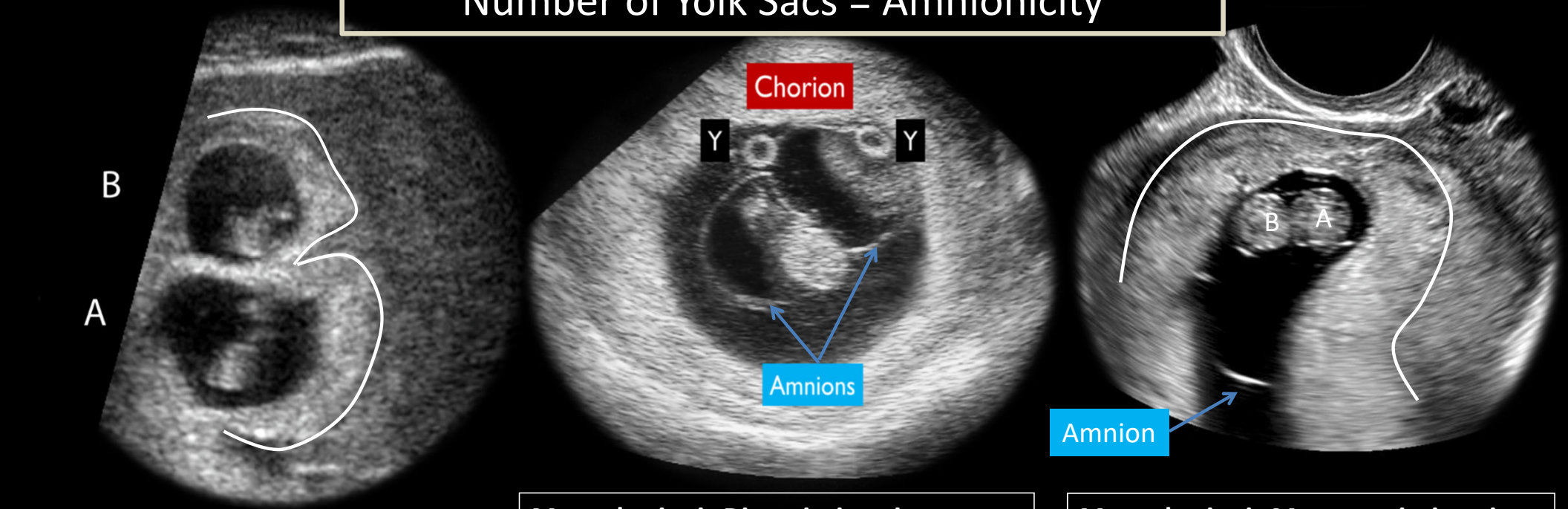

Dichorionic Diamniotic twins:
Two thick chorionic sacs, each surrounding one embryo.

Monochorionic Diamniotic twins:
One thick chorionic sac surrounding both embryos. Each embryo surrounded by thin amnion. 2 Yolk sacs (Y).

Monochorionic Monoamniotic twins:
One thick echogenic chorion, one thin amnion, both embryos inside single amniotic sac.

Monochorionic Monoamniotic Pregnancy

Monochorionic twins: single yolk sac

Monochorionic twins: Single thick chorionic sac

Number of Yolk sacs
=
Amnionicity!

Single Yolk sac
=
Monoamniotic!

Embryos flanking each side of and sharing a single yolk sac
=
Monochorionic Monoamniotic pregnancy

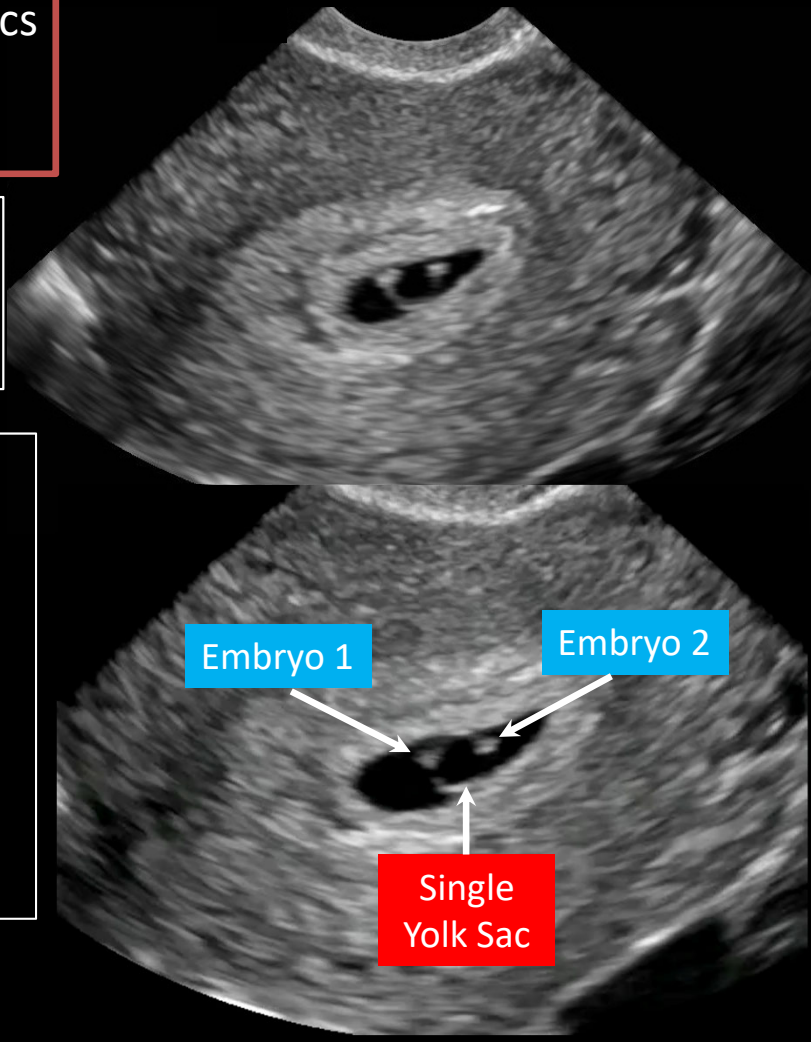

Pitfall: Synechia in Monochorionic Diamniotic Pregnancy Mimicking a Dichorionic Diamniotic Pregnancy

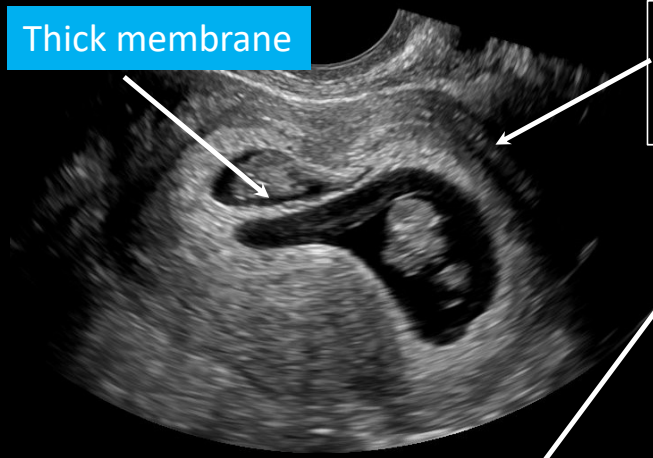

Suggestion of "thick" membrane
Same echogenicity as chorion

Other views demonstrate additional thin membranes ??

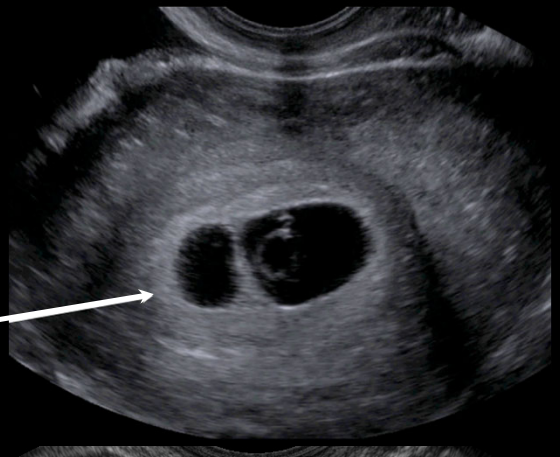

Single Chorionic Sac

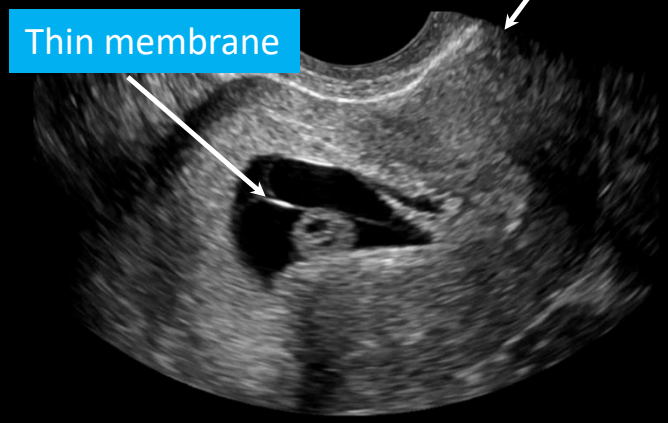

CONTINUOUS thin membrane,
DISCONTINOUS thick membrane

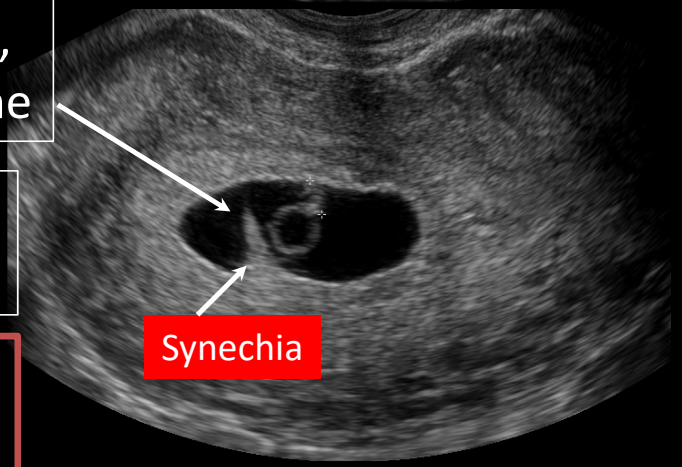

Chorionic reaction along synechia

Monochorionic Diamniotic pregnancy

Pitfall: MoDi Pregnancy Mimicking a MoMo Pregnancy. A case of missing membranes!

5 weeks 5 days

Single placenta = Monochorionic

11 weeks 3 days

2 Yolk Sacs, one with each embryo

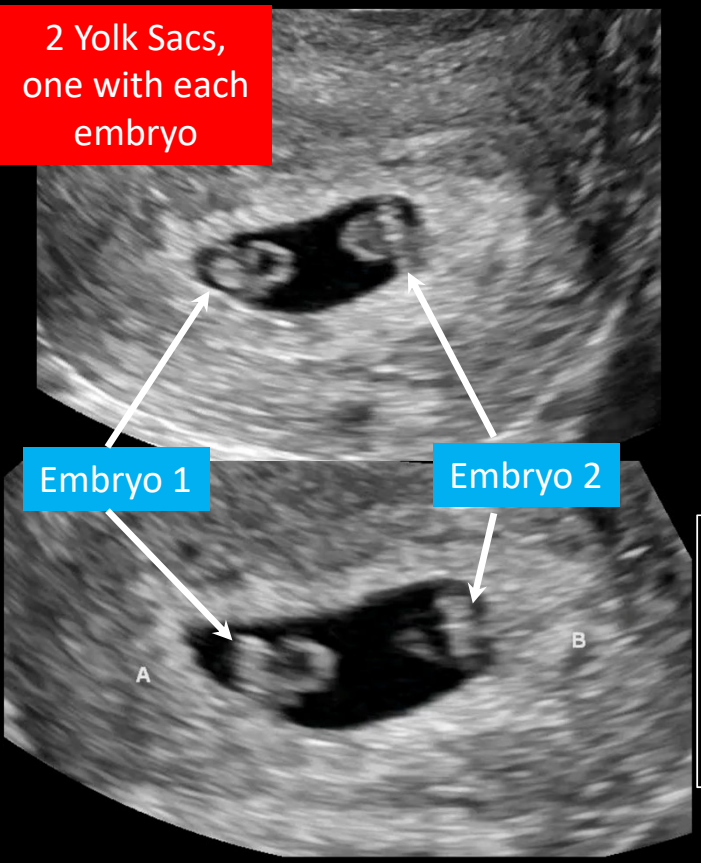

Two embryos and two yolk sacs
No membrane present?
Diamniotic or Monoamniotic?

Follow up at 11w3d
Membrane now visualized

PITFALL: Membrane may be below sonographic detection in early MoDi pregnancy up to *7-9 weeks gestation*

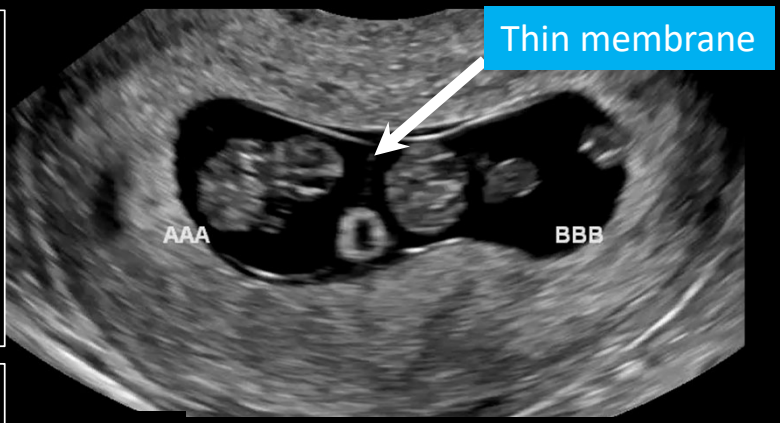

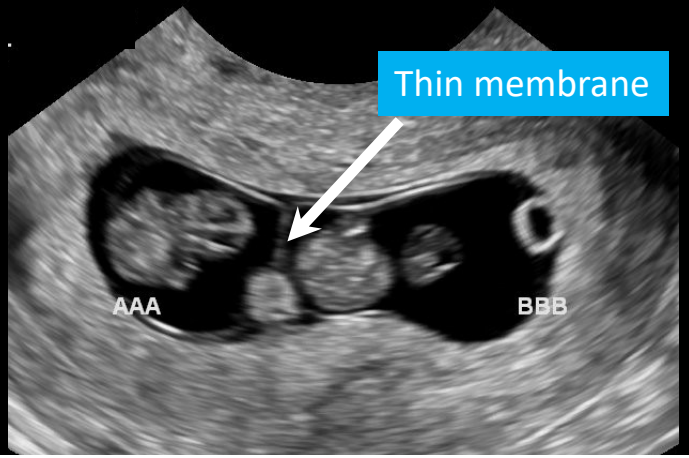

Single intrauterine pregnancy seen at REI with 2 mm crown- rump length, 8 week follow-up exam

Two for the price of one!

Twin embryos present.
Single Yolk Sac & Embryo
=
Monochorionic
Monoamniotic

Single Yolk Sac

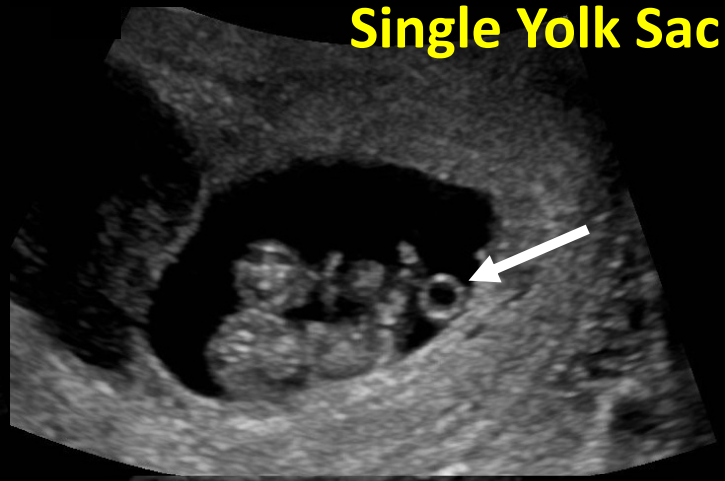

Single Amnion

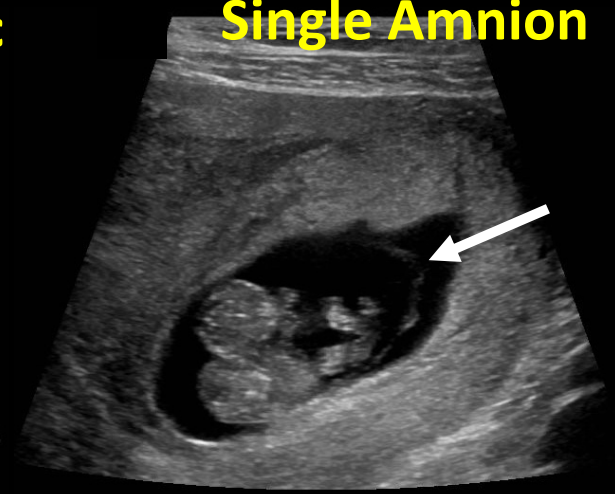

Are they conjoined?

Difficult to be certain.
Cardiac axis looks different.
Follow-up needed to ensure embryos are separable.

Chorionicity and Amnionicity in the Second Trimester

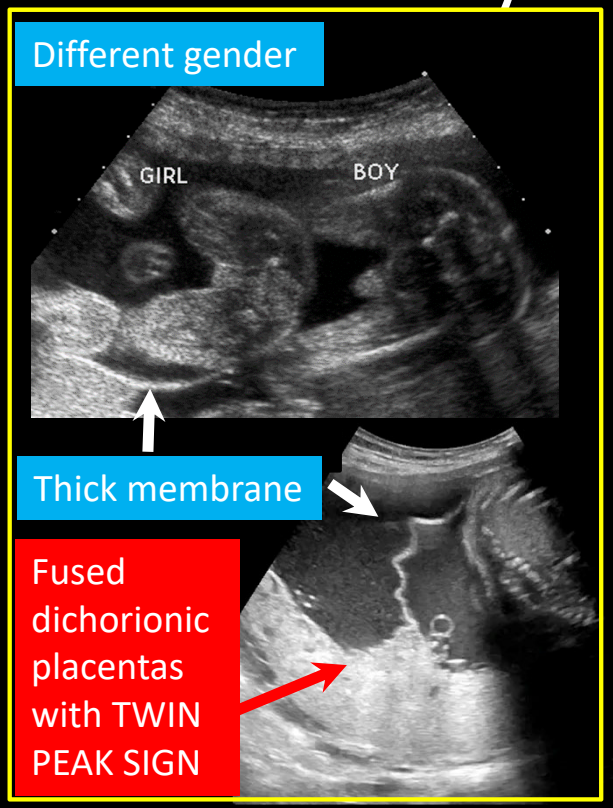

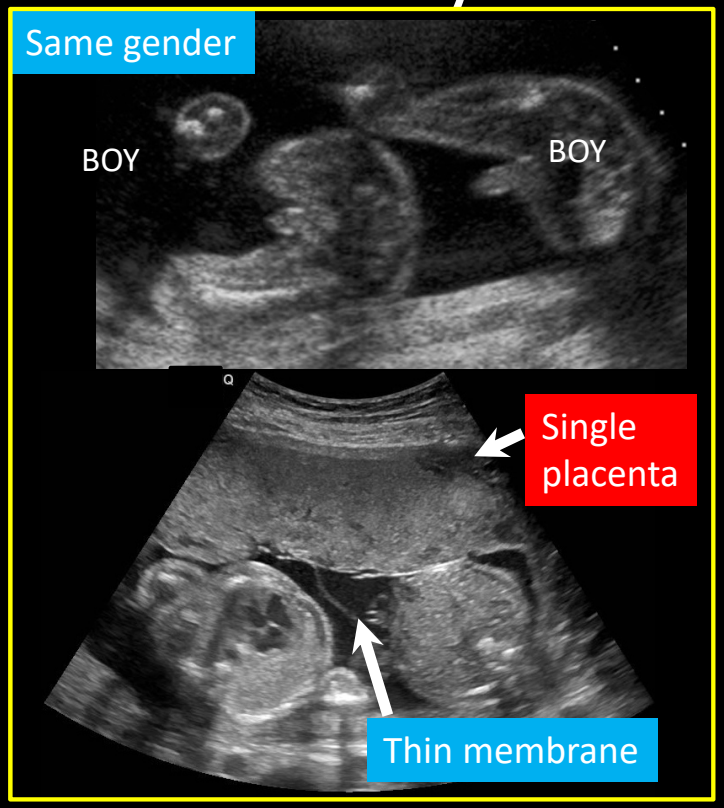

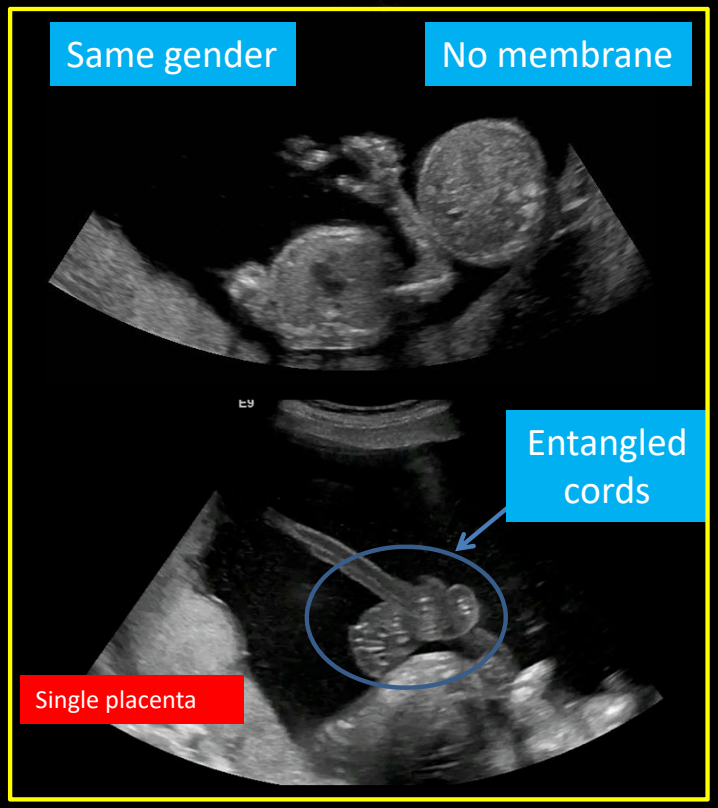

Dichorionic twins:
Two placentas (separate or fused)
Different gender = dizygotic
THICK membrane

Monochorionic twins:
Single placenta
Same gender
THIN inter-twin membrane

Monoamniotic twins:
Single placenta
Same gender
No inter-twin membrane
ENTANGLED CORDS

Monochorionic Monoamniotic Conjoined Twins

Thoracopagus

Single anterior placenta

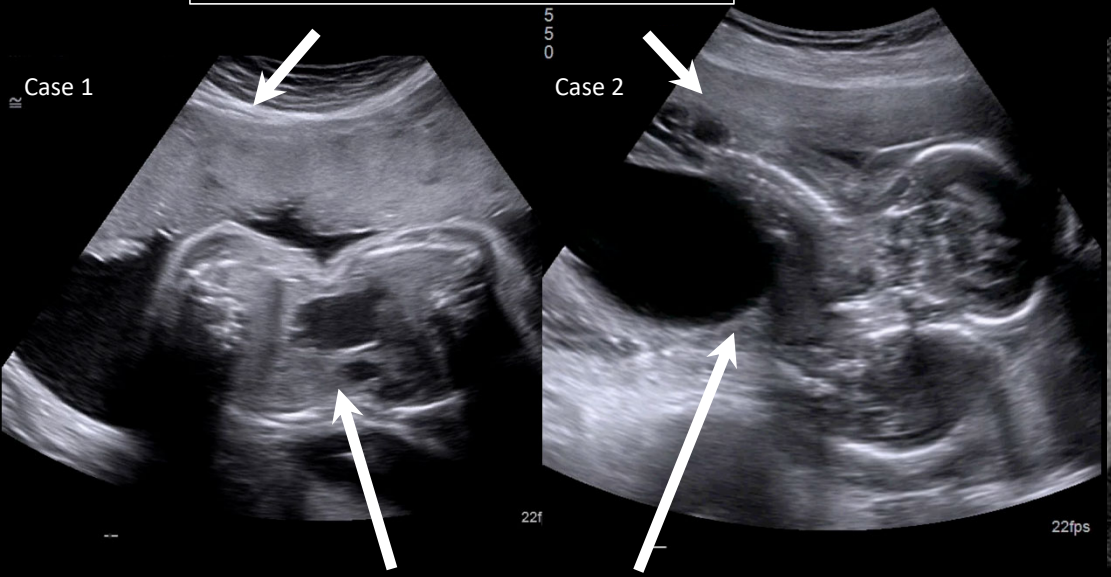

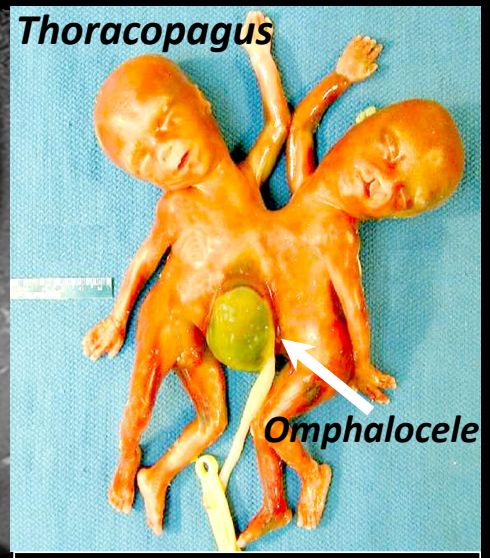

Conjoined *thoracopagus* twins with shared hearts

- Incidence of conjoined twins: 10.25 per million births
- High mortality: Only 18% of prenatally diagnosed conjoined twins survive
- Increased incidence of structural anomalies not associated with conjoined organs

MRI redemonstrates conjoined twins with shared hearts

Specimen after pregnancy termination in a 4th case demonstrates thoraco-omphalopagus twins.

Complications Affecting a Monochorionic Pregnancy

Complications of unbalanced flow

1. Twin-twin transfusion syndrome (TTTS)
2. Twin anemia polycythemia sequence (TAPS)
3. Unequal placental sharing *(selective IUGR)*

Complications from in utero co-twin demise

1. High incidence of mortality.
2. Spectrum of mild to severe neurologic injury
3. Was called twin embolization; now known to be ischemic injury of survivor

Other complications

1. Twin reverse arterial perfusion syndrome (TRAP)
2. Discordant anomalies
3. Monoamniotic twins
4. Conjoined twins

Monochorionic Placenta & Placental Vascular Connections

Intraplacental vascular connections between the twin circulations

Normal vascular supply to single twin, no communication to other twin

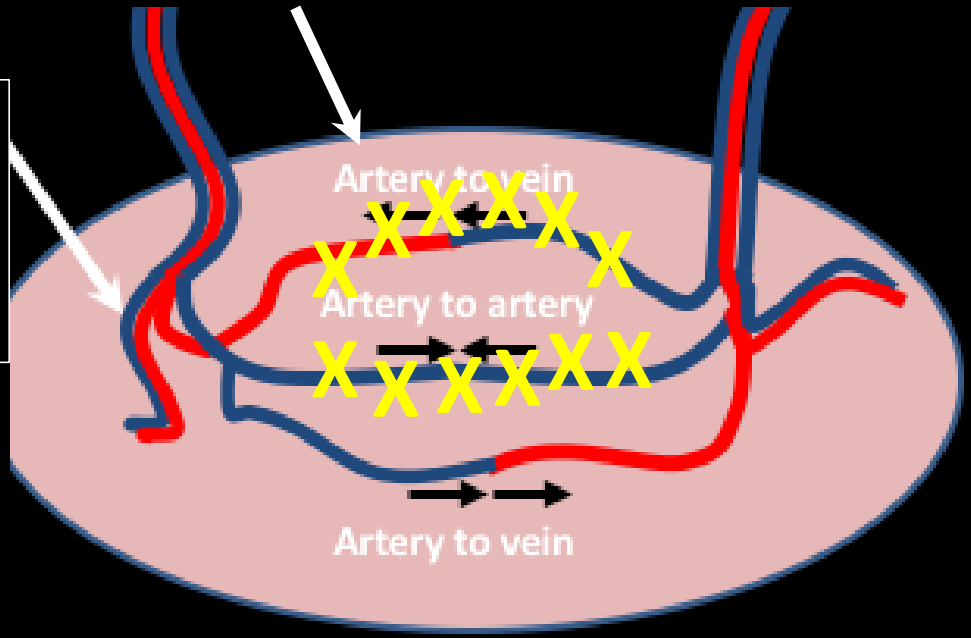

Balanced State
A-V inflow = outflow
A-A present

Protective A-A Anastomosis
Twins pumping blood to each other

Unbalanced State
A-V inflow ≠ outflow
Blood flow from one twin to another

Effects of Unbalanced Flow in a Monochorionic Twin Pair

1. Anemia
2. Oliguria
3. Oligohydramnios
4. Circulatory insufficiency
5. Growth restriction
6. Heart failure
7. Fetal demise

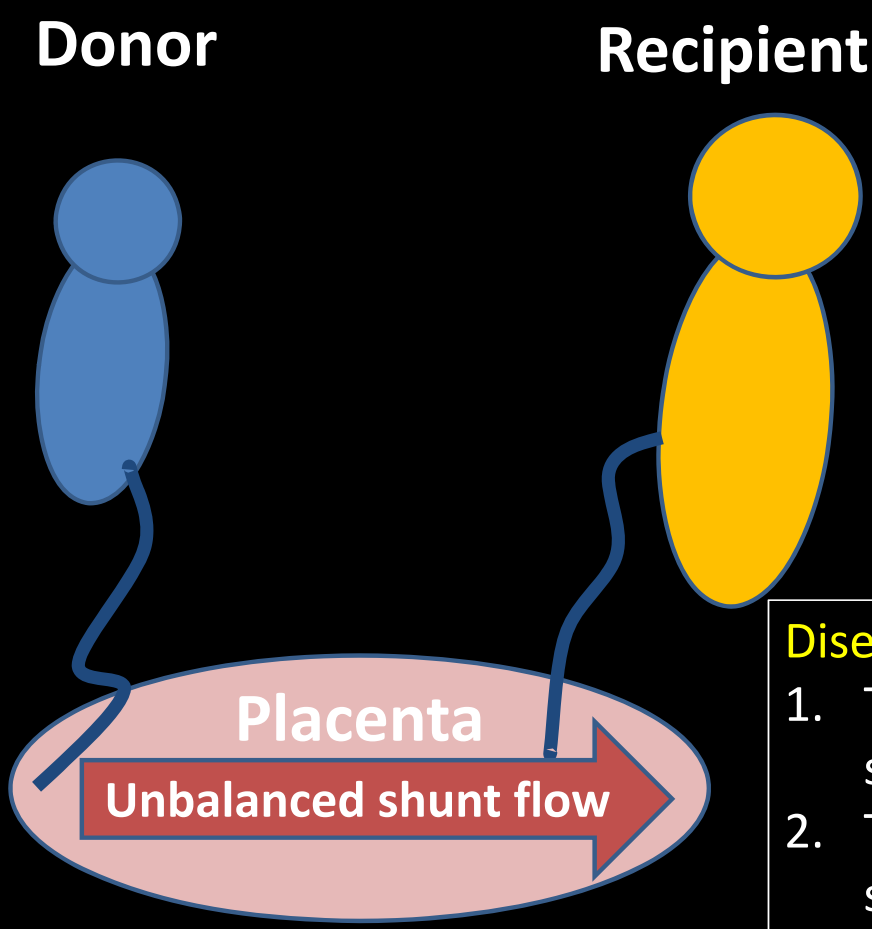

1. Polycythemia
2. Polyuria
3. Polyhydramnios
4. Circulatory overload
5. Heart failure
6. Fetal demise

Donor twin often has marginal or velamentous placental cord insertion

Disease states:

1. Twin-twin transfusion syndrome (TTTS)
2. Twin anemia polycythemia sequence (TAPS)
3. Unequal placental sharing

Surveillance of Monochorionic Twins: Initiation, Timing, and Duration

- Initial scan--> confirm living monochorionic pair
- Establish twin identity at first scan—identify placental cord insertion, discordant anomalies, or growth
- *Maintain identity for all future follow-ups*
- Ultrasound every 2 weeks → Starting at 16 weeks to delivery
- Growth scan q 4 weeks per NAFTA recommendations *(institutional protocols vary from 2-4 weeks)*

TWIN-TWIN TRANSFUSION SYNDROME
- ✓ Bladder and amniotic fluid
- ✓ Multivessel Doppler- Umbilical Artery, Vein and Ductus venosus

TWIN ANEMIA POLYCYTHEMIA SEQUENCE
- ✓ Middle cerebral artery velocity measurement
- ✓ Calculate Multiples of Median (*ref:* perinatology.com)

UNEQUAL PLACENTAL SHARING/SELECTIVE IUGR
- ✓ Check fetal weights
- ✓ Calculate weight discordance

- Anatomy scan at 18-22 weeks
- *Role of Fetal Echocardiography*- ↑Risk of cardiac defects in monochorionic twins, both embryologic defects and physiologic changes from unique placental vascular connections
  - Perform at 18-22 weeks in uncomplicated monochorionic twin gestation

Monochorionic Diamniotic Pregnancy with Unequal Placental Sharing

Single placenta

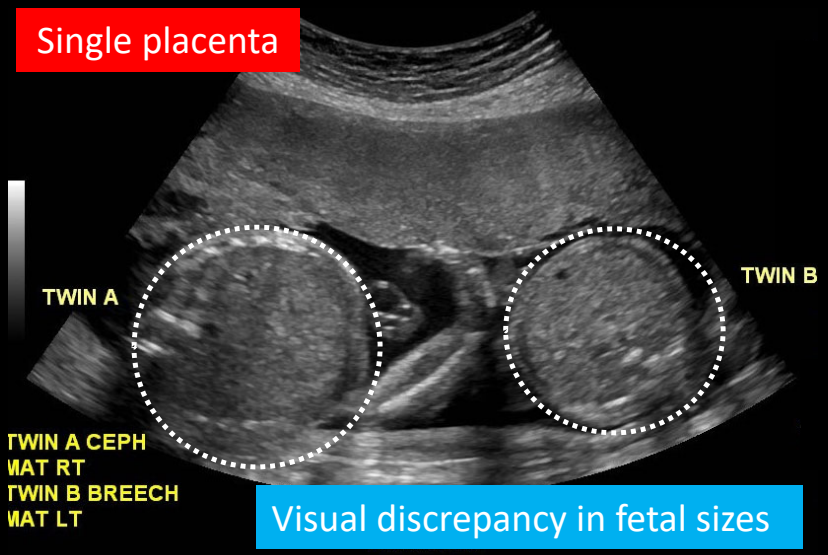

Visual discrepancy in fetal sizes

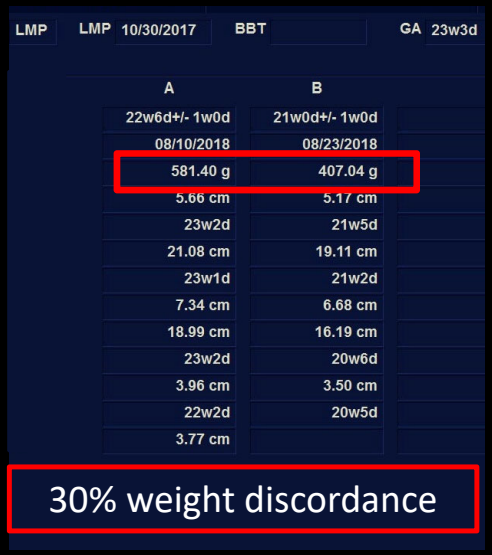

30% weight discordance

Velamentous cord insertion: smaller twin

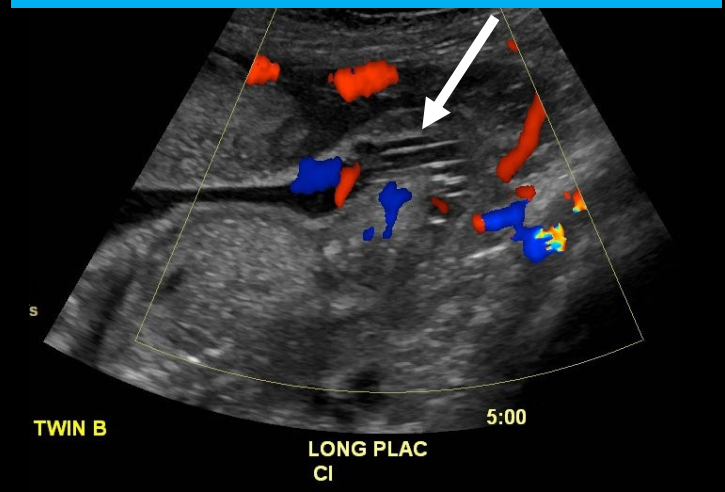

- Single anterior placenta shared by monochorionic twins
- Weight discordance 30%
- Velamentous cord insertion of the smaller twin

Calculating weight discordance

$$\frac{\text{Larger twin weight - Smaller twin weight}}{\text{Larger twin weight}}$$

>25% weight discordance and/or fetal weight < 10th percentile constitutes unequal placental sharing

MoDi Pregnancy with Unequal Placental Sharing

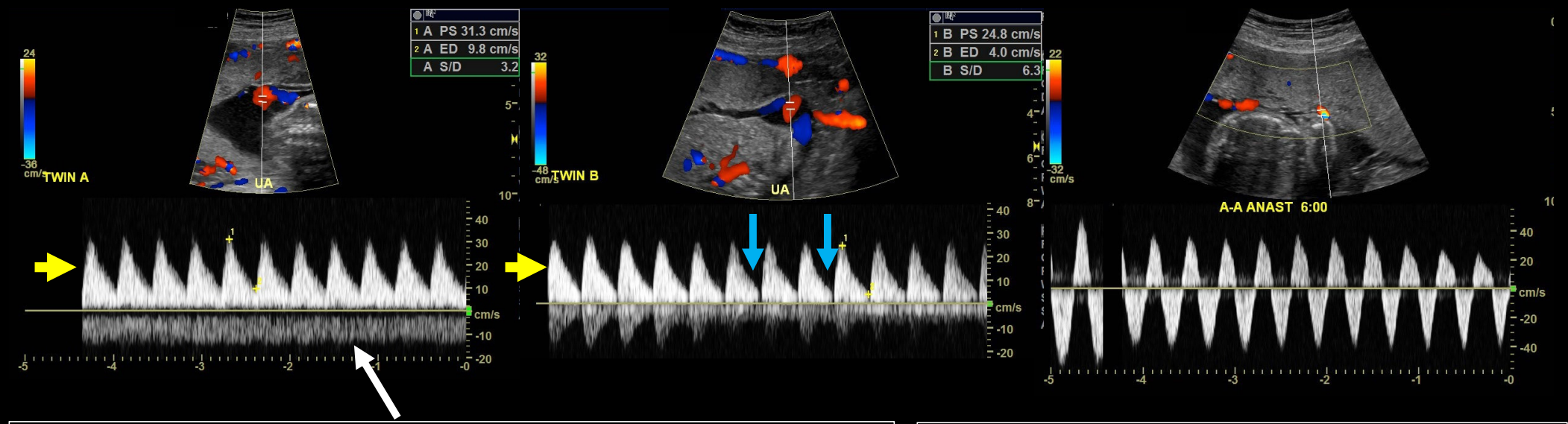

- Normal UA Doppler with forward diastolic flow (yellow arrows)
- Normal antegrade umbilical vein flow without pulsatility (white arrow)
- Occasional loss of end-diastolic flow can sometimes be seen in the setting of an A-A (blue arrows)

- Arterial-arterial (A-A) anastomosis is demonstrated with *to and fro* flow
- Sometimes protective against TTTS
- Creates a balanced state
- To look for an A-A, search along the placental surface with color Doppler

Stage 1 Twin-Twin Transfusion Syndrome

Single placenta

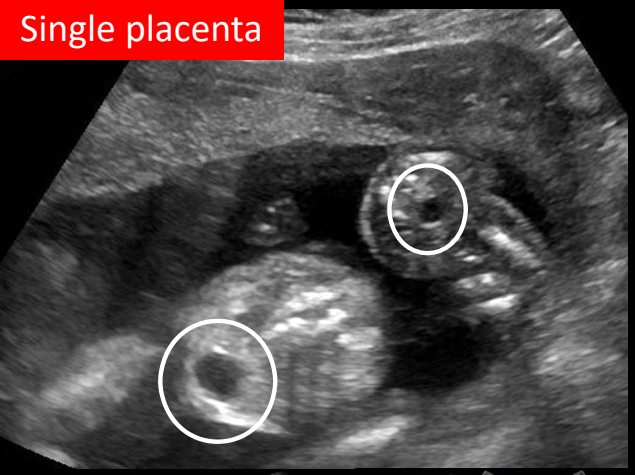

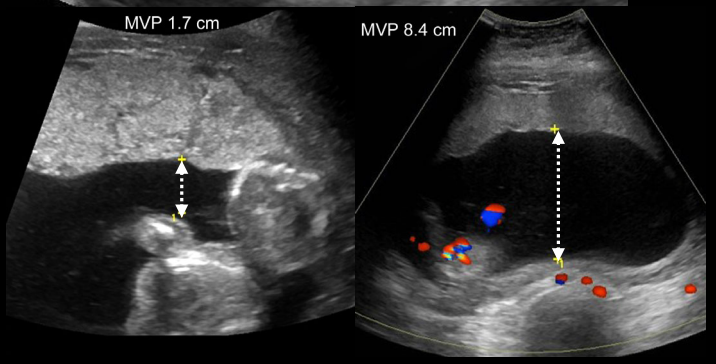

Oligohydramnios
DVP= 1.7 cm

+

Polyhydramnios
DVP= 8.4 cm

+

Bladders (circle) visible in both twins

=

Stage 1 TTTS

Quintero staging for TTTS

- **Stage I**: Oligohydramnios in donor twin and polyhydramnios in recipient twin (Oli-Poly)
- **Stage II**: Absent bladder in the donor twin
- **Stage III**: Doppler abnormalities in the umbilical artery and/or umbilical vein
- **Stage IV**: Fetal hydrops
- **Stage V**: Fetal demise

Oli-Poly
↓
Absent bladder
↓
Doppler abnormalities
↓
Fetal hydrops
↓
Fetal demise

1. Prognostic value
2. Stepwise progression is expected but not always the norm
3. Often twin pairs can "skip" stages with progressive TTTS

Stage 2 TTTS Complicating a Monochorionic Diamniotic Pregnancy

Recipient

Polyhydramnios
DVP= 9.8 cm

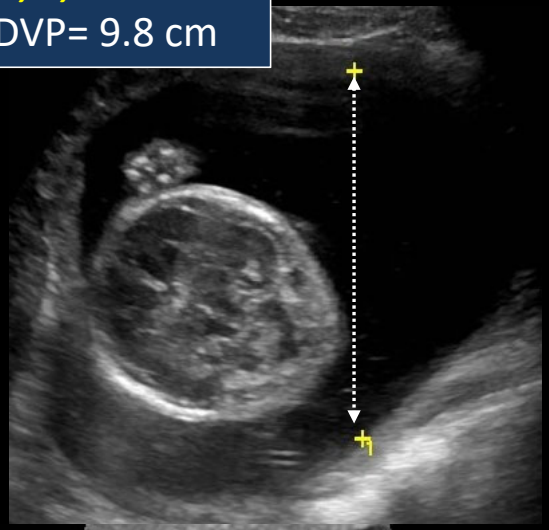

Bladder present

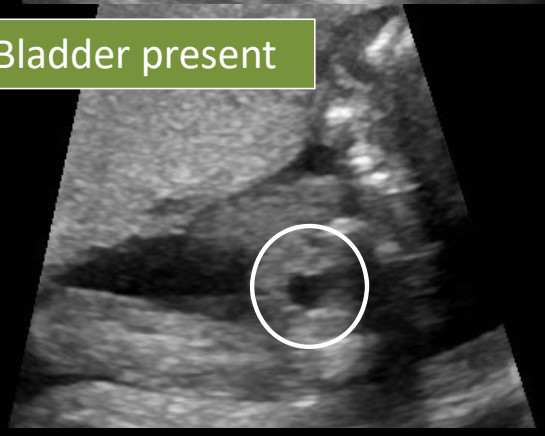

Single placenta

Stuck twin (donor)

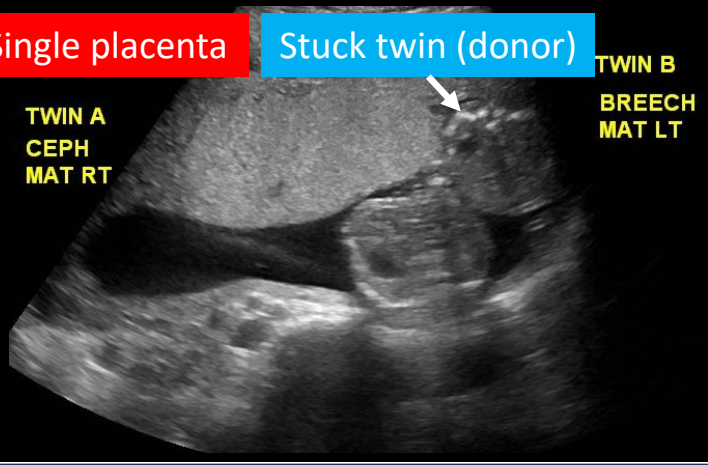

Donor oligohydramnios
&
Recipient polyhydramnios

+

Donor bladder non-visualized

=

Stage 2 TTTS

Donor

Oligohydramnios
DVP= 0.7 cm

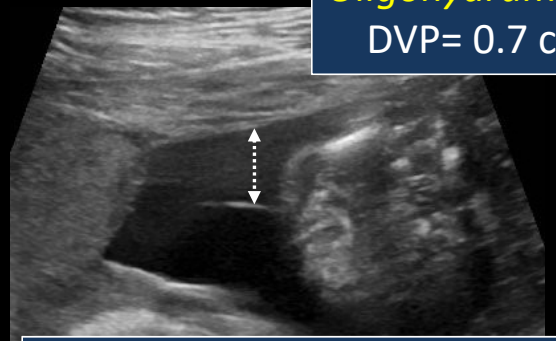

Note difference in echogenicity of the 2 amniotic cavities

Bladder absent

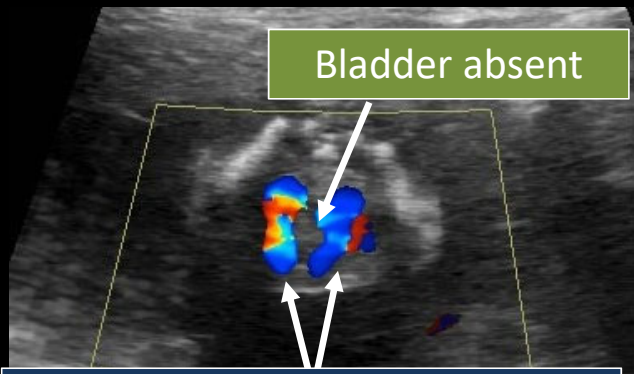

Bilateral umbilical arteries expected to encircle the bladder

Stage 2 TTTS Complicating a Monochorionic Monoamniotic Pregnancy

Single shared posterior placenta

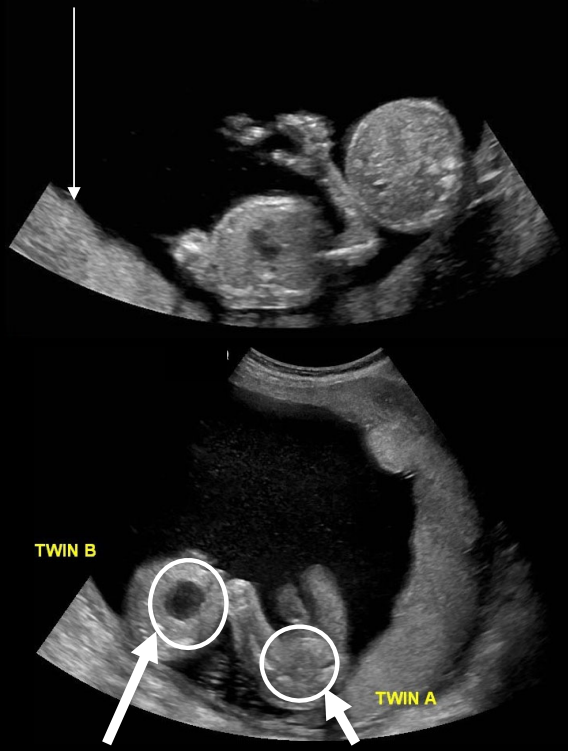

Central CI* for recipient

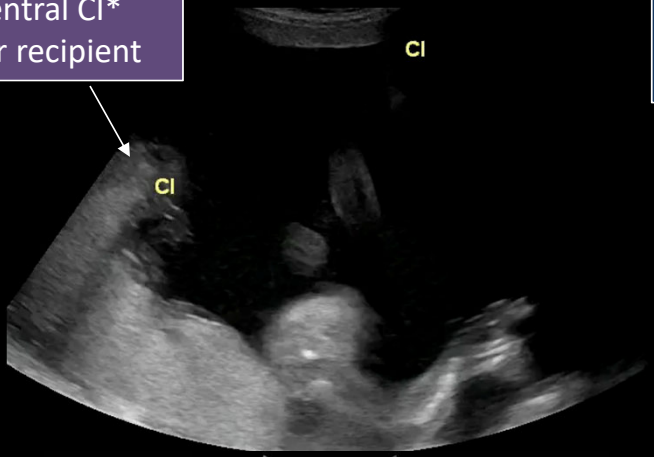

Entangled cords → MoMo pregnancy

Velamentous CI for donor*

1. Challenging diagnosis due to single amniotic space.
2. Polyhydramnios is the clue.
3. Absent bladder in one of the twins = Stage 2 TTTS

Bladder present + Bladder absent in donor + *Polyhydramnios* DVP= 15 cm = Stage 2 TTTS

*CI= Cord insertion

Stage 3 Twin-Twin Transfusion Syndrome

Stuck twin (donor), anhydramnios

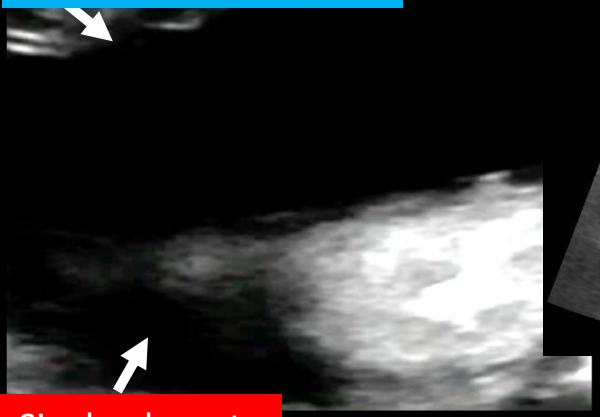

Single placenta

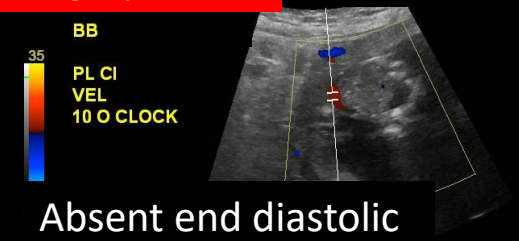

Absent end diastolic flow in donor

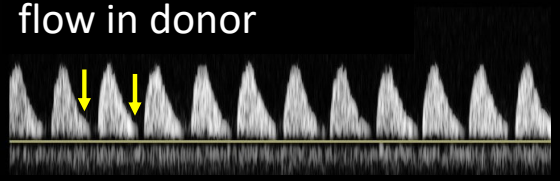

Bladder absent in donor

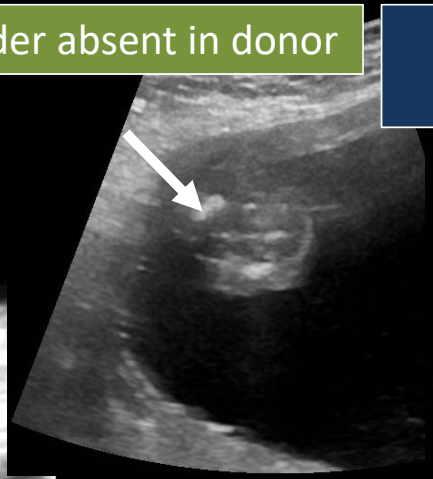

Polyhydramnios
DVP= 9.5 cm in recipient

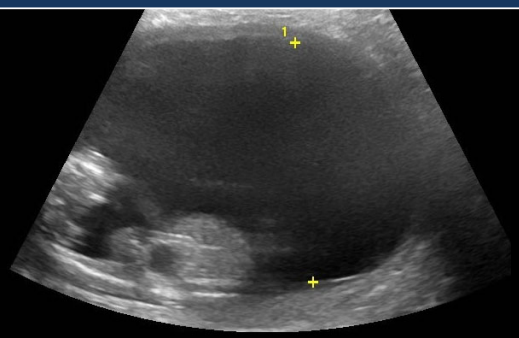

Donor oligohydramnios
&
Recipient polyhydramnios

+

Donor absent bladder

+

Doppler abnormality in Donor

=

Stage 3 TTTS

Planning images demonstrate sonographic window for intraoperative guidance of laser ablation procedure.

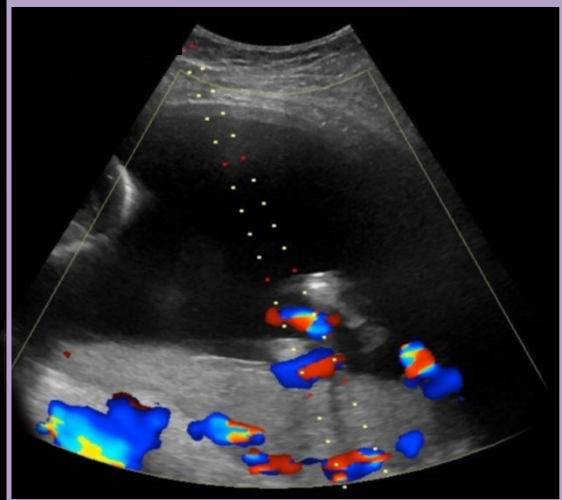

Stage 4 Twin-Twin Transfusion Syndrome

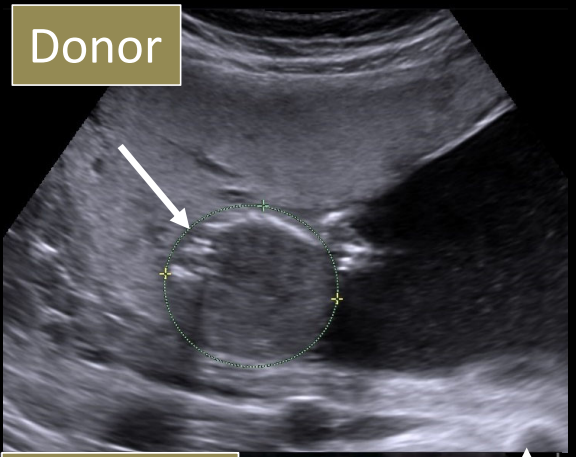

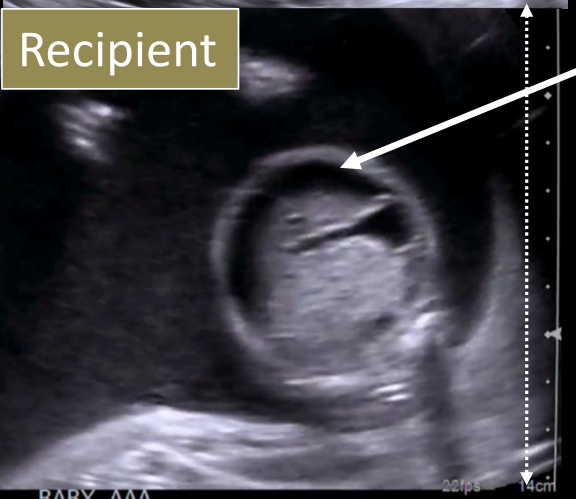

Stuck Donor Twin with *anhydramnios*

+

Recipient twin with polyhydramnios and *hydrops* (ascites shown here)

=

Stage IV TTTS

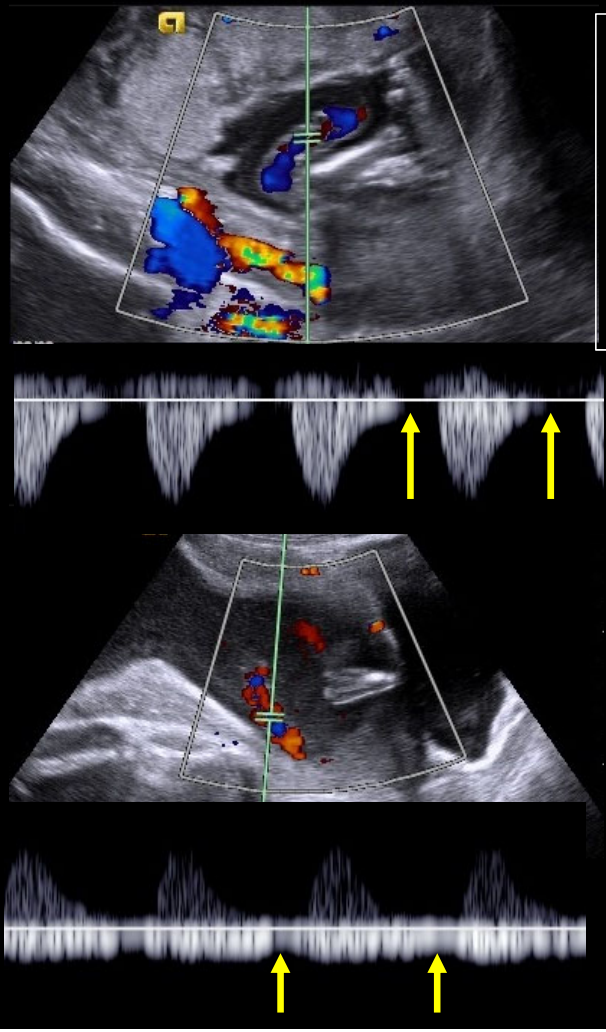

Recipient umbilical artery waveform shows *absent end diastolic flow (arrows)*

Recipient umbilical vein waveform shows *pulsatile flow (arrows). Pulsatile flow in the UV is a premorbid waveform*

Treatment for Twin-Twin Transfusion Syndrome

- Fetoscopic laser ablation
  - Quintero stage II–IV disease
  - Gestational age between 16 weeks 0 day and 26 weeks 0 day of gestation
  - Maternal complications such as placental abruption (1%) and intra-abdominal leakage of amniotic fluid (3%)
  - Goal: Laser coagulation of the entire vascular equator
- Ultrasound surveillance with MCA Doppler after treatment
  - Weekly to assess for recurrent twin-twin transfusion syndrome or the development of twin anemia–polycythemia sequence for 6 weeks
  - Then, every 2 weeks as with uncomplicated monochorionic gestation
- Amnioreduction for non-laser candidates (after 26 weeks)
- Selective feticide/Radiofrequency ablation (rarely performed):
  - Usually performed after 16 weeks
  - Discordant for a major structural abnormality
  - One of the twins is moribund
  - Severe IUGR of one twin

Fetoscope entry into recipient sac with polyhydramnios. Donor Sac and placenta are not transgressed.

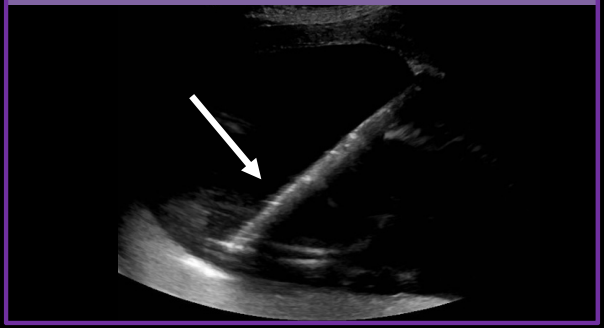

New ascites (FF) in mother with markedly reduced amniotic fluid around the recipient (arrow) post procedure, suggestive of amniotic leak.

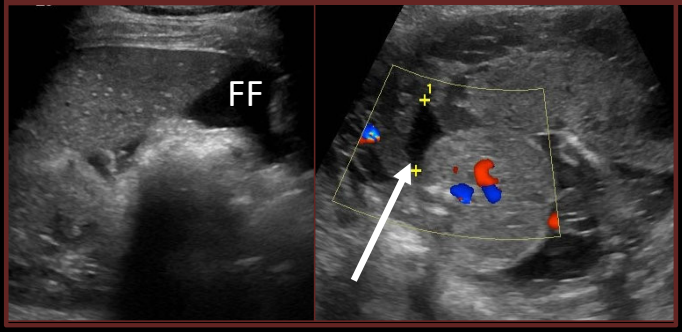

Complication after Laser: Chorioamniotic Separation

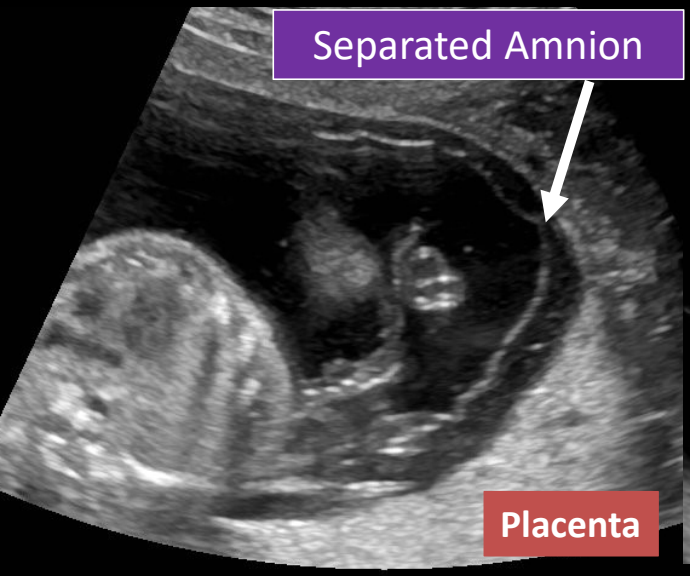

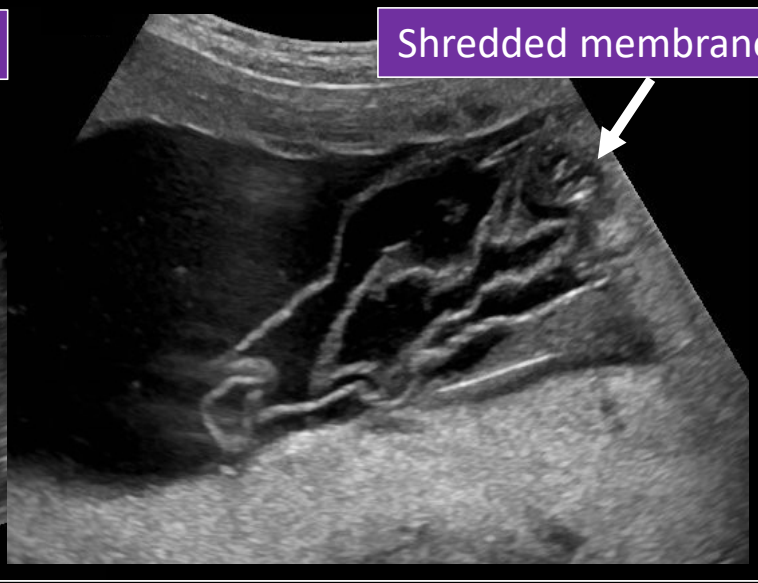

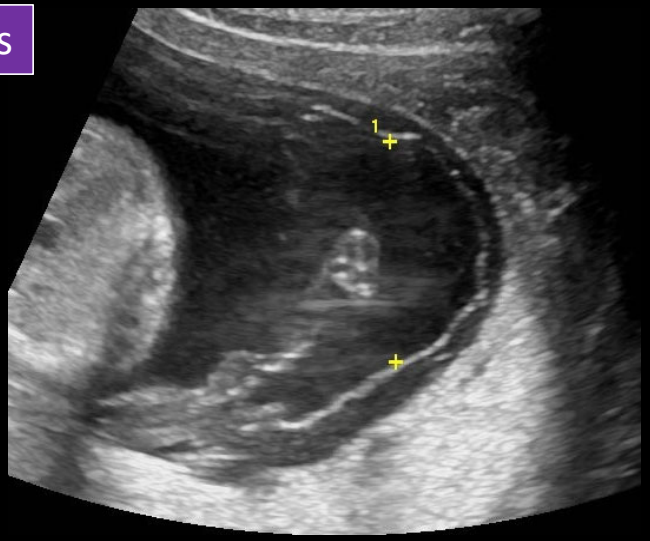

Post procedurally, a membrane is seen outlining the amniotic surface of the placenta and continuing along the uterine body, representing the amnion separated from the chorion. Shredded membranes were also visible.

Understanding the Chorioamniotic space: The chorion and amnion are separate in early pregnancy and fluid is present between them. Eventually, this potential space is obliterated and fluid can re-enter this space as a procedural complication. FACT: Chorion and amnion never fuse with each other; this is a common misconception.

Correct method of measuring DVP after CAS.
Space outside the amnion should *not* be included in the measurement.

Twin Reverse Arterial Perfusion Sequence

28 year old woman with twin pregnancy, provided history of embryonic demise of one twin

Single placenta/chorion

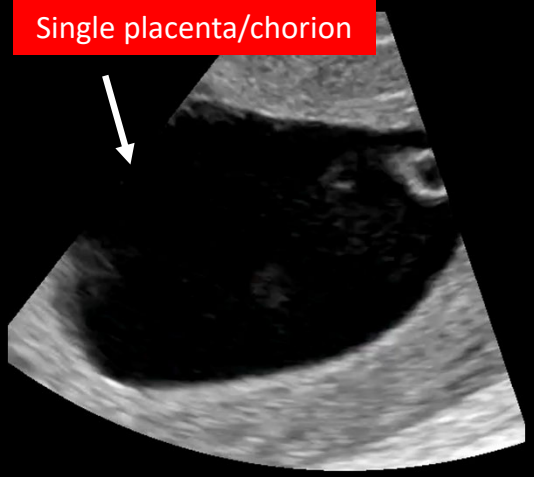

"Demised" twin

Living twin

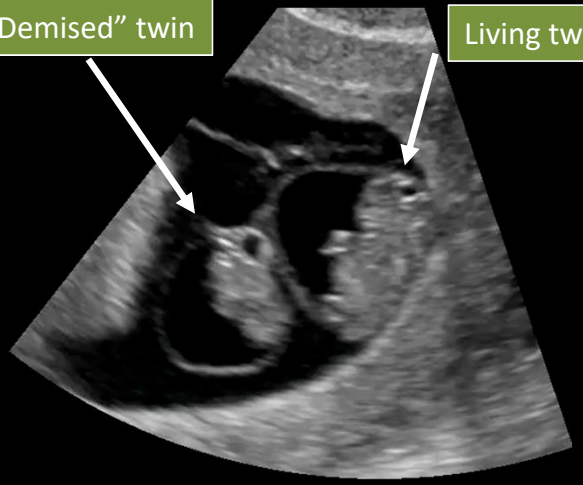

No embryonic cardiac motion

Follow-up after 6 weeks

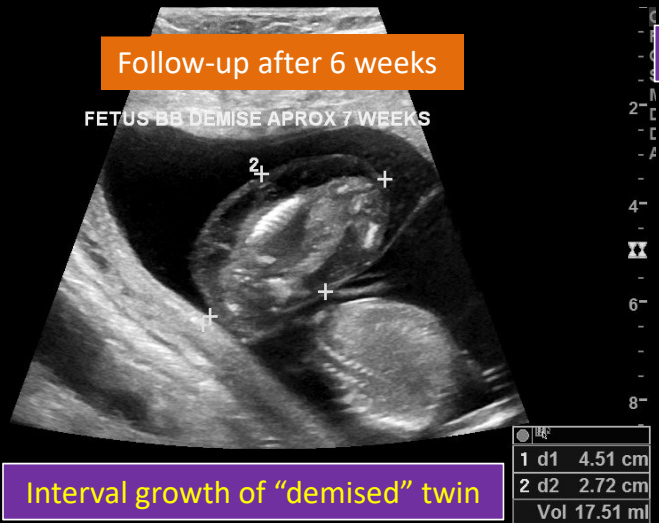

Interval growth of "demised" twin

Reversed umbilical arterial flow in anomalous twin

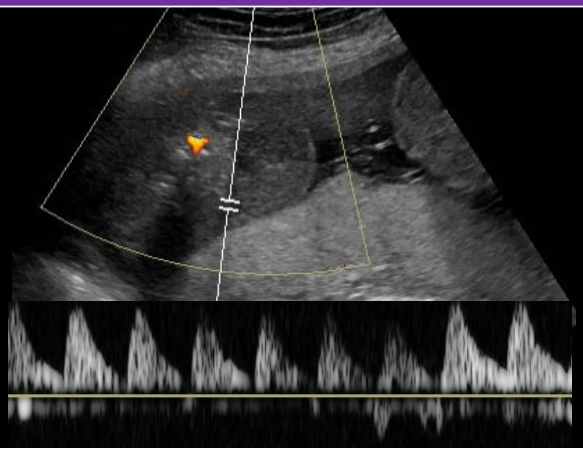

Interval growth of anomalous embryo ➡ *severely edematous fetus*

+

Reversed umbilical arterial flow

=

Twin Reverse Arterial Perfusion Sequence

Twin Reverse Arterial Perfusion Sequence

- Monochorionic twins
- Abnormal placental connections
- TRAP twin abnormal head, torso
  - May have NO cranial structures
- Can have a rudimentary heart
  - Acardiac twin is a misnomer

Outcomes:

1. Self devascularization
2. Pump twin hydrops/demise
   (~50% chance of pump twin demise)
3. Treat with radiofrequency ablation

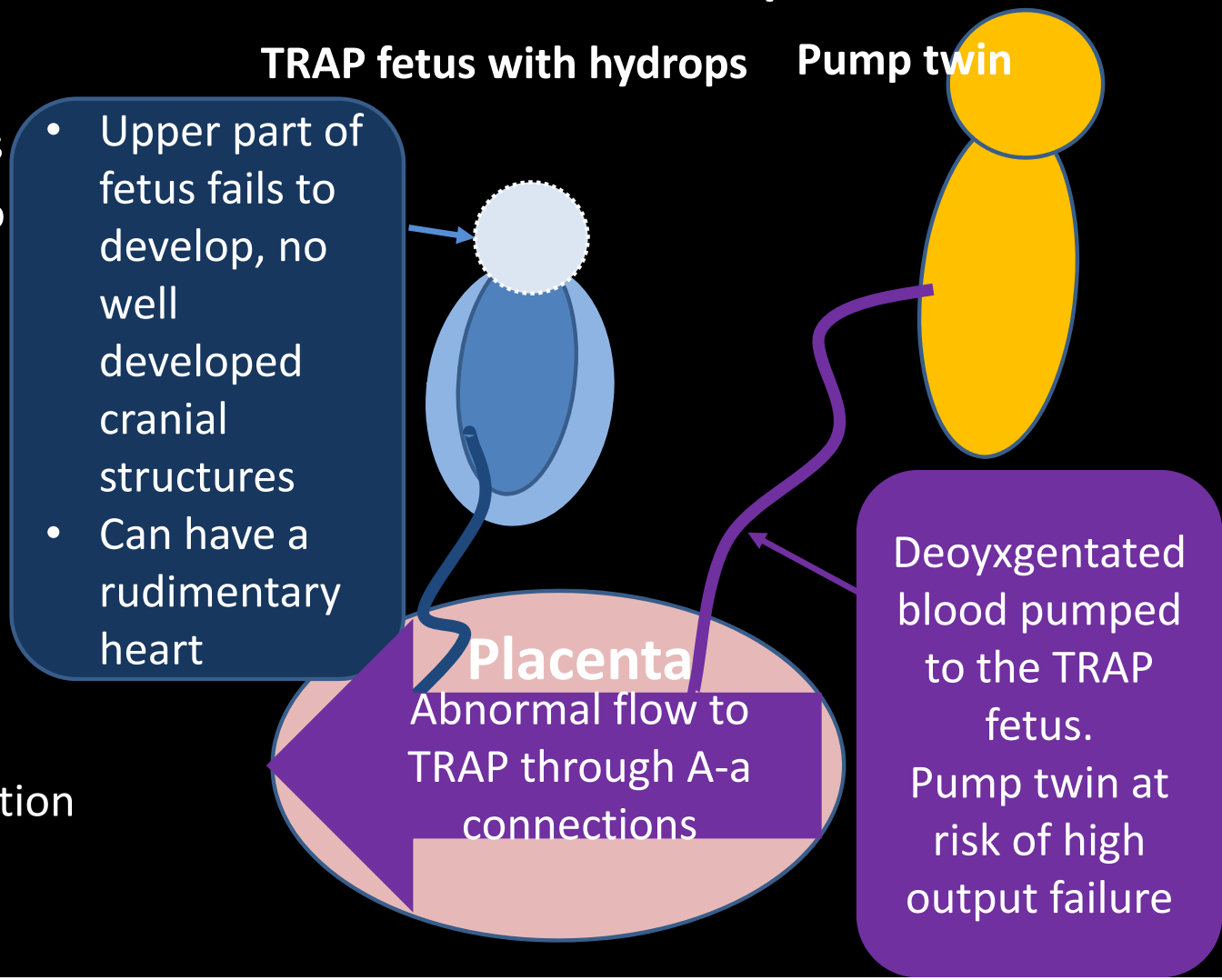

Twin Reversed Arterial Perfusion Sequence

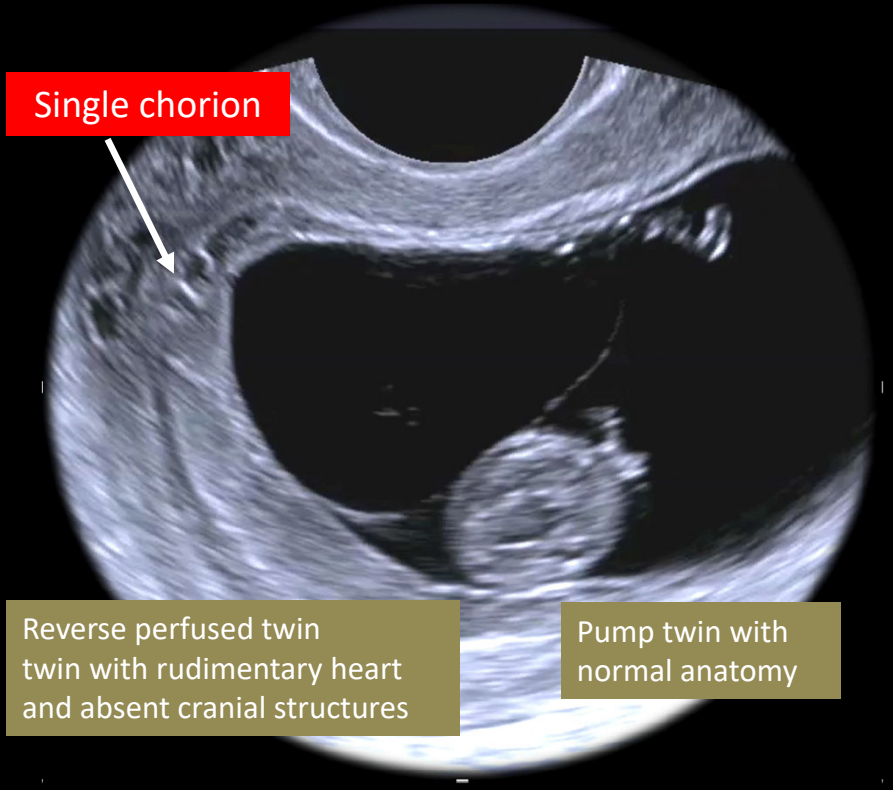

TVUS at 10 weeks shows monochorionic diamniotic twins. Both demonstrated cardiac activity. One was hydropic and lacked normal cranial structures. The other was normal.

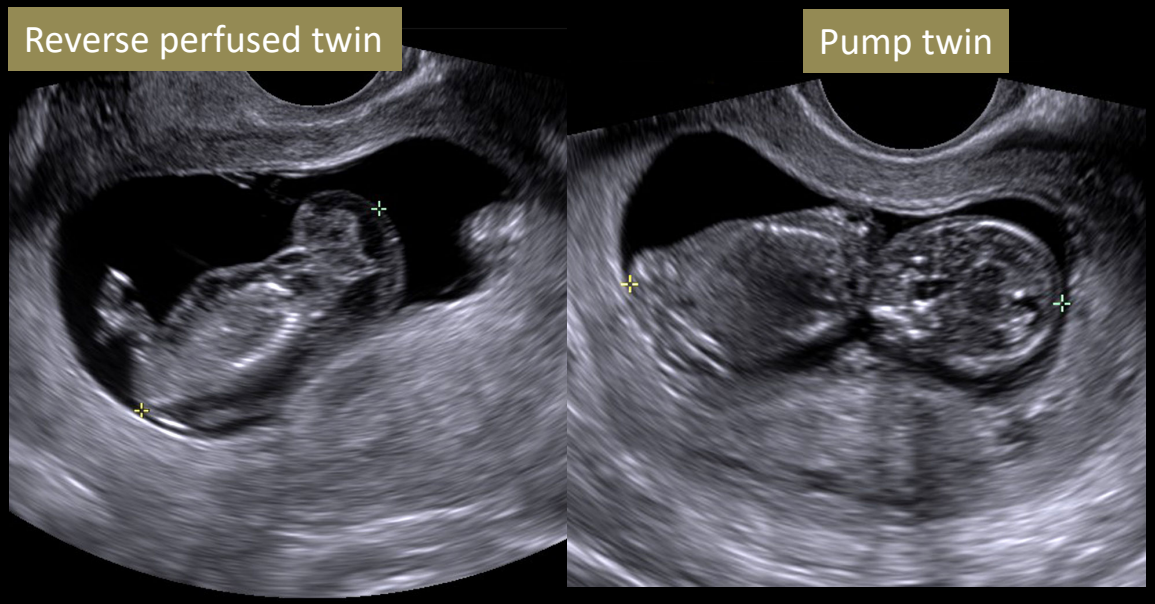

TVUS at 12 weeks showed demise of both the reverse perfused twin and the pump twin.

The abnormal twin cannot survive ex-utero and management of this condition is focused on wellbeing of the pump twin. Hence, radiofrequency ablation of the abnormal twin is performed.

Radiofrequency Ablation of Abnormal TRAP Twin

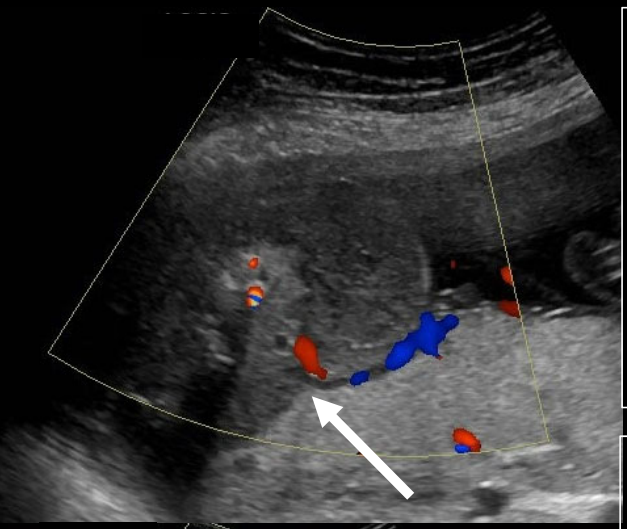

Abnormal twin with perfusion and flow within the cord (arrow) demonstrated on color Doppler US.

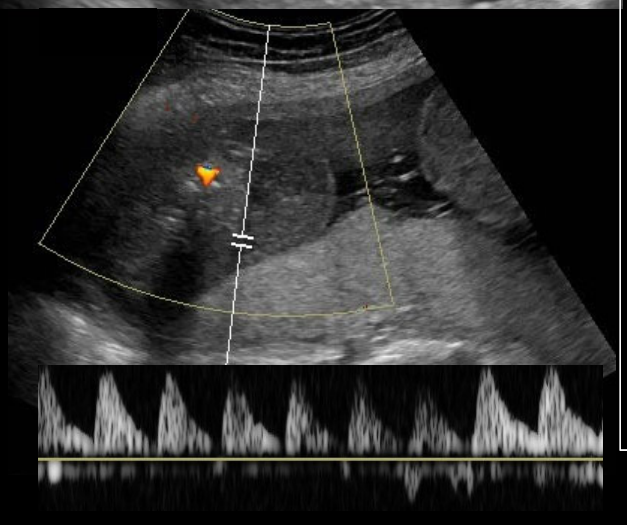

Spectral Doppler US demonstrates *arterial flow flowing towards the abnormal twin*, consistent with twin reverse arterial perfusion sequence.

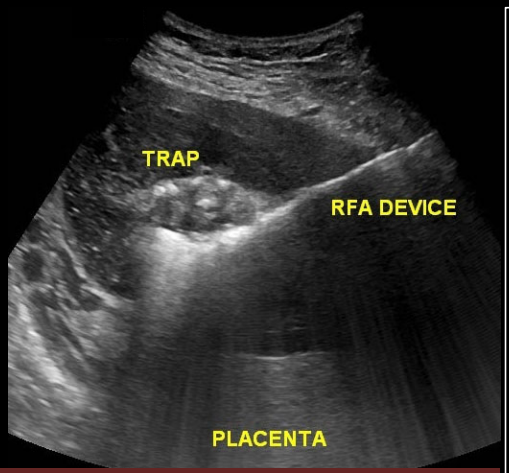

Correct placement of a radiofrequency ablation (RFA) device with the *tip at the abdominal cord insertion.*
Unlike the fetoscope, the RFA device can be placed through the placenta due to its smaller size.

Post-delivery image demonstrating the anterior abdominal wall defect post RFA

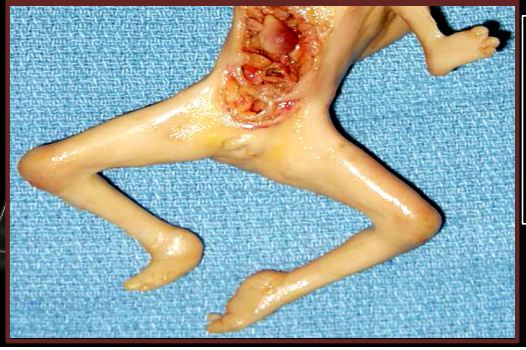

No residual flow within the TRAP twin after RFA

Pitfall: Post RFA of the Abnormal TRAP Twin

Note the high scale for Doppler interrogation. Such a high scale coupled with high gain settings predisposes to twinkle artifact.

Adjusting the scale lower and using appropriate gain can help reduce artifact and assess true flow to the TRAP twin.

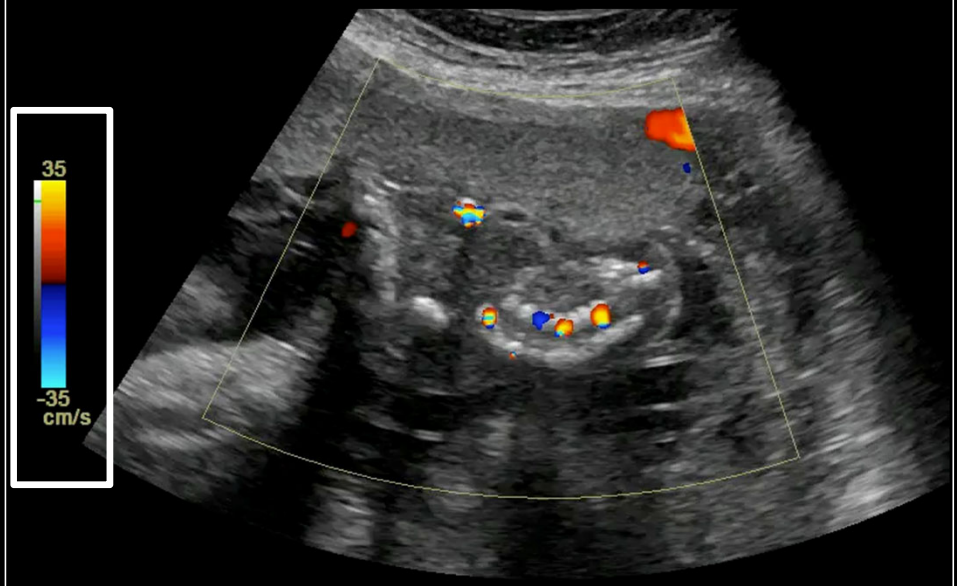

32 week MoDi pregnancy after RFA of TRAP twin. Color Doppler images demonstrate a large amount of signal throughout the TRAP twin. This represents "*twinkle artifact*" from the osseous structures of the abnormal twin.

PITFALL: Do not misinterpret as presence of flow.

Twin Anemia Polycythemia Sequence

Thin membrane

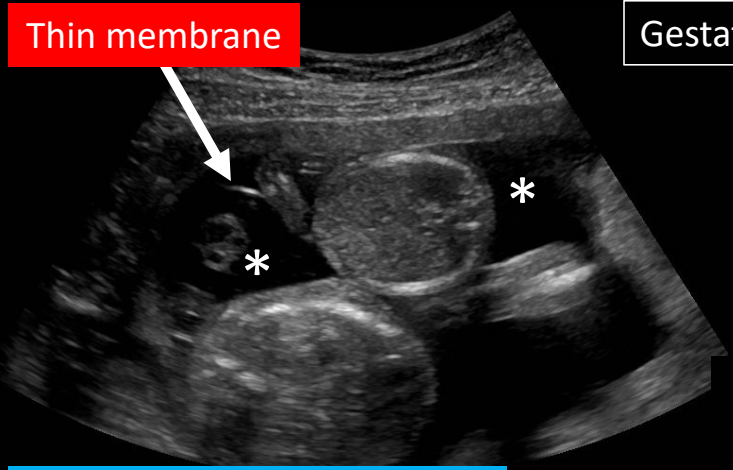

Normal fluid in both sacs (*)

Gestational age= 19 wks 3 days

Discordant MCA Peak Systolic Velocities (PSV)

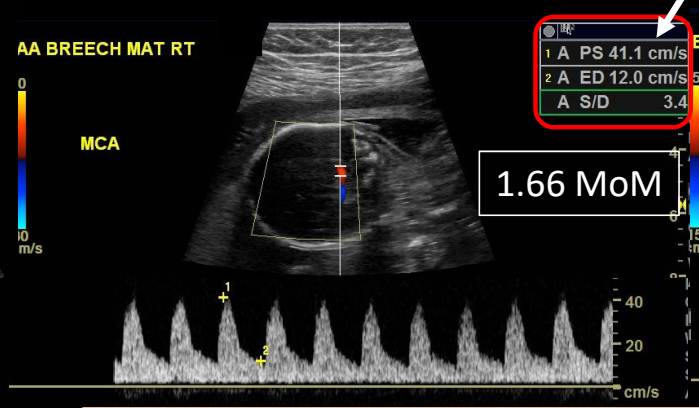

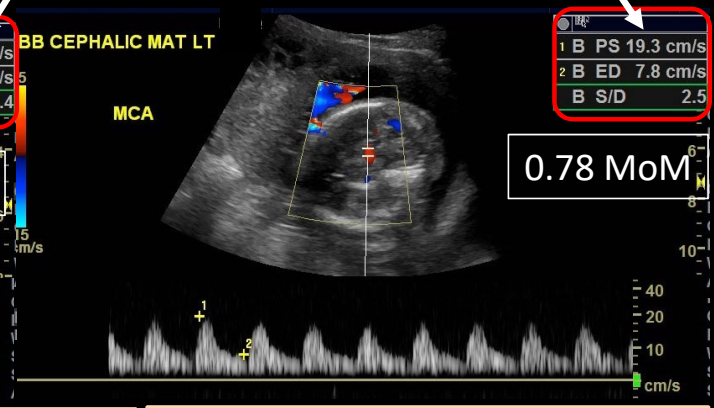

Discordant MCA PSV

+

Normal fluid and bladders

=

Twin Anemia Polycythemia Sequence

Calculating Multiples of Median

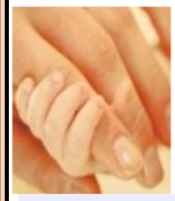

perinatology.com

Expected Peak Velocity of Systolic Blood Flow in the MCA as a Function of Gestational Age

Enter values here

ENTER:

Gestational age (weeks)

Observed MCA Peak Systolic Velocity (cm/sec)

Calculate Clear Form

Calculations:

The Median Peak Systolic Velocity for this age is

Your measurement is Multiples of Median

Results

Interpreting Multiples of Median

Polycythemia: <1.0 MoM

Anemia : >1.5 MoM

Demise of One Twin of a Monochorionic Pair

- Subsequent high risk of death & severe cerebral injury to surviving twin
- Suspected mechanism: *Acute exsanguination* of the surviving twin into the *low-pressure vascular circuit of the deceased twin* through patent vascular anastomoses
- → Sudden and profound hypotension, hypovolemia, and anemia
- → → Consequent *tissue hypoxia and acidosis* (earlier theory of intertwin embolization has largely been abandoned)
- Urgent delivery after an unwitnessed twin death unlikely to improve the co-twin's outcome and may unnecessarily expose the survivor to complications of prematurity.
- *Expectant management* to term is favored

Porencephaly with anechoic spaces lining the ventricular wall, in a previously normal brain after co-twin demise

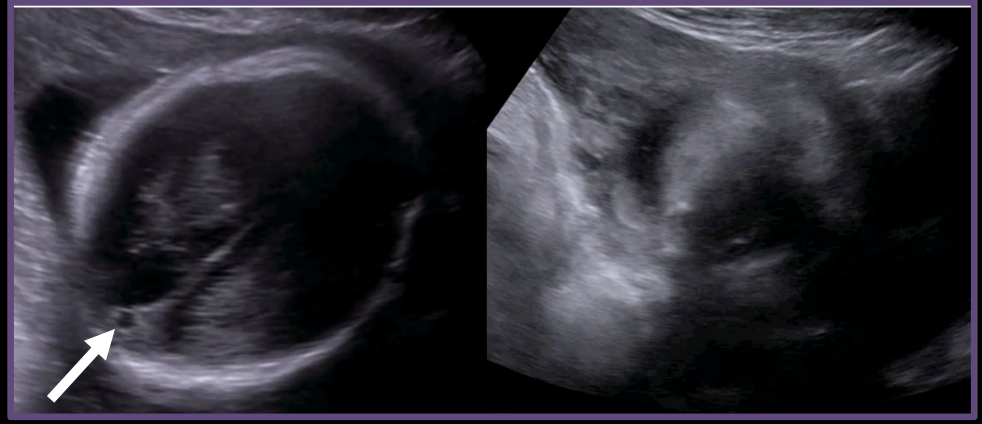

Dilated heart in a surviving twin after co-twin demise, representing ischemic cardiomyopathy in the surviving twin. This twin also had ischemic brain injury.

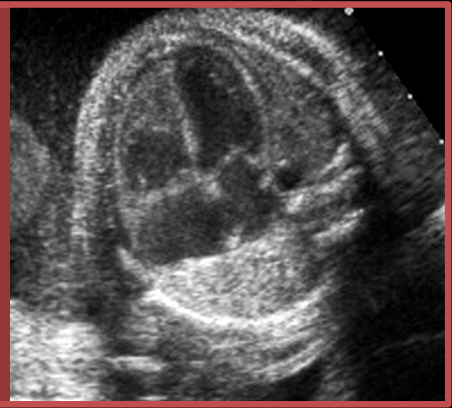

Demise of one twin of a monochorionic pair

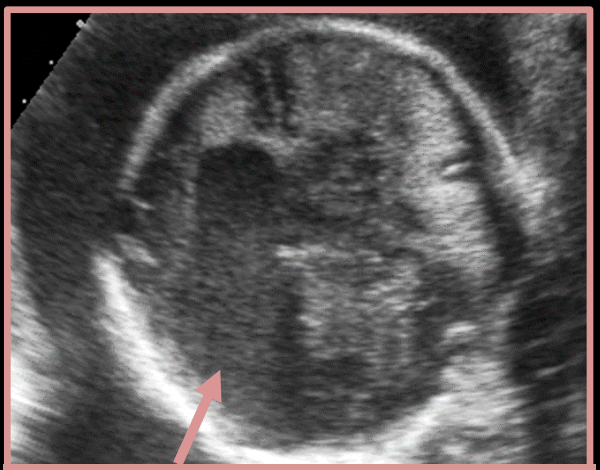

Surviving twin demonstrates large right parietal infarct and diffuse left cerebral hemisphere ischemia. The brain was previously structurally normal.

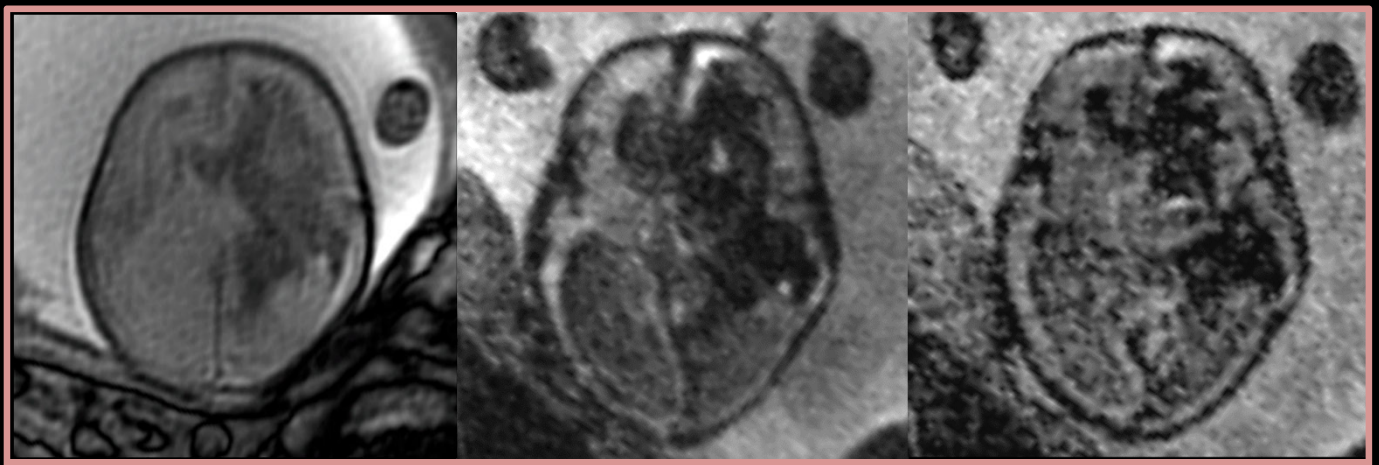

Corresponding fetal MR images (a) T2-weighted (b) diffusion and (c) ADC sequences: demonstrate large right parieto-temporal infarction with large area of cortical necrosis and diffuse left cerebral hemisphere ischemia.

Ischemic injury is possible to multiple organ systems

CENTRAL NERVOUS SYSTEM
Ventriculomegaly
Porencephaly
Cerebral atrophy
Microcephaly

CARDIOVASCULAR SYSTEM
Ischemic cardiomyopathy

GASTROINTESTINAL TRACT
Small bowel atresia

GENITOURINARY TRACT
Renal cortical necrosis

Discordant Anomalies

- Monochorionic twins assumed to be genotypically identical
- May be *phenotypically discordant for major congenital malformations*
- Structural anomalies more common than in singletons & dichorionic twins
- Major anomalies: 6–8% of monochorionic twins vs 1–2% of dichorionic twins
- *Usually affects only one fetus*
- Discordant anomalies *may also negatively affect healthy co-twin*
- Intrauterine demise due to anomalies or aneuploidy → Co-twin at risk of demise (10–25%) or cerebral damage (24–45%)

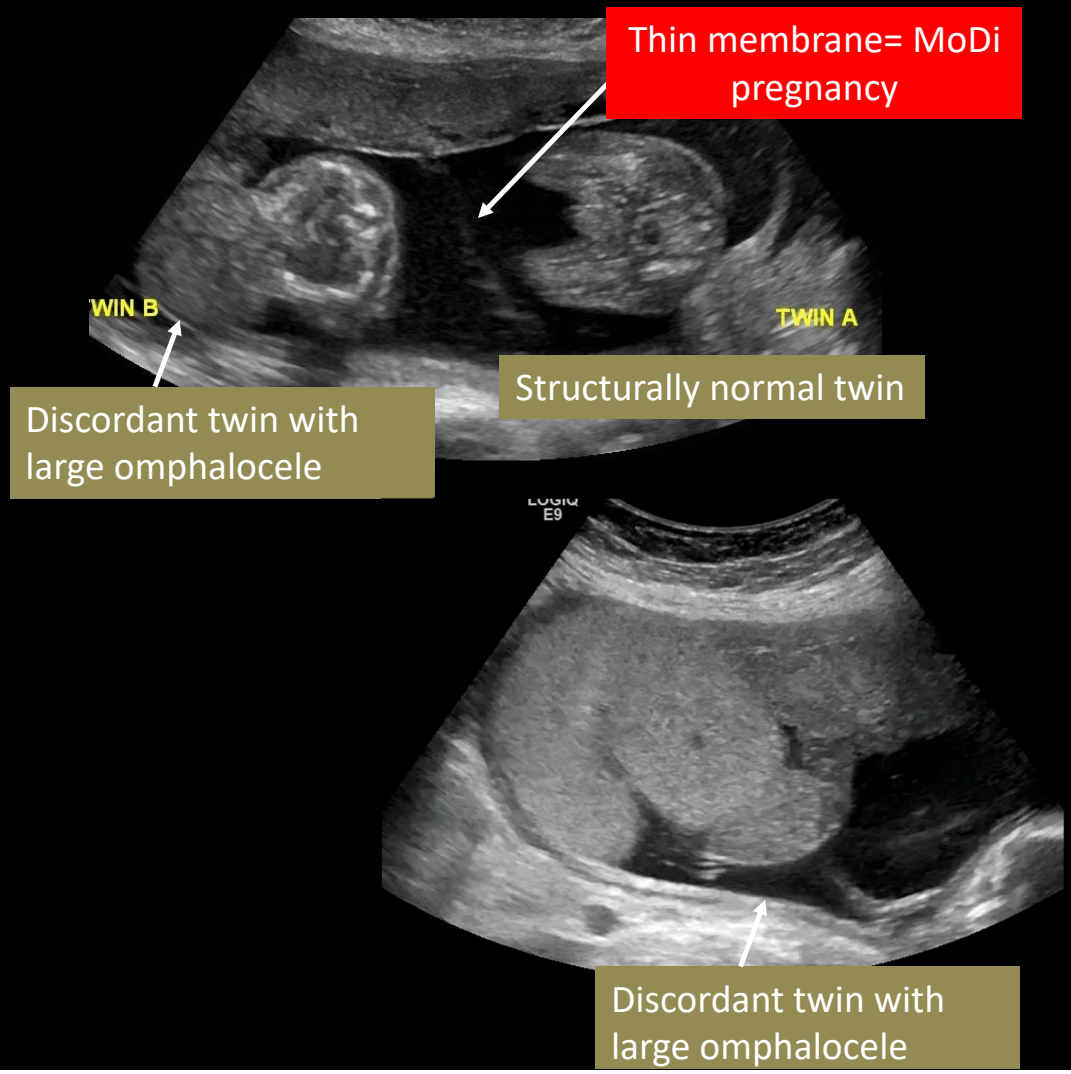

Higher-Order Multiples

- High-order multifetal gestations containing a monochorionic twin pair are at increased risk of adverse pregnancy outcomes.
- Lower birth weight
- Lower gestational age at delivery
- Spend more days in the NICU
- Increased risk of intrauterine death, selective growth restriction, delivery less than 32 weeks of gestation, and a lower survival rate in dichorionic triplets than in trichorionic triplets.
- Option of reducing the monochorionic pair.

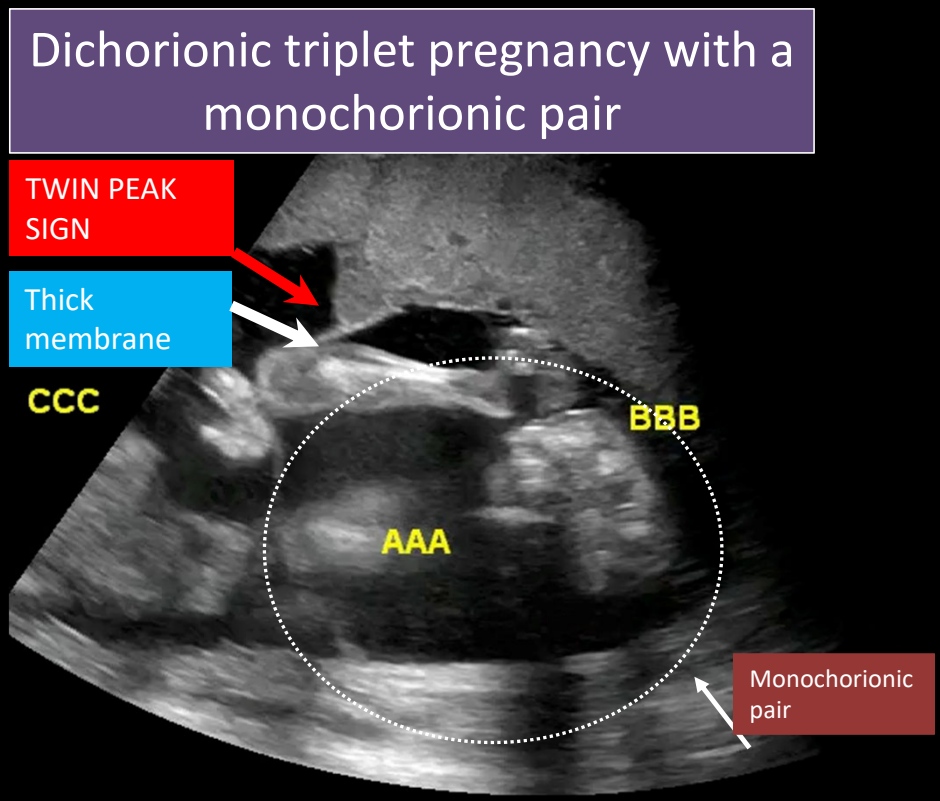

Referral to a Fetal Treatment Center

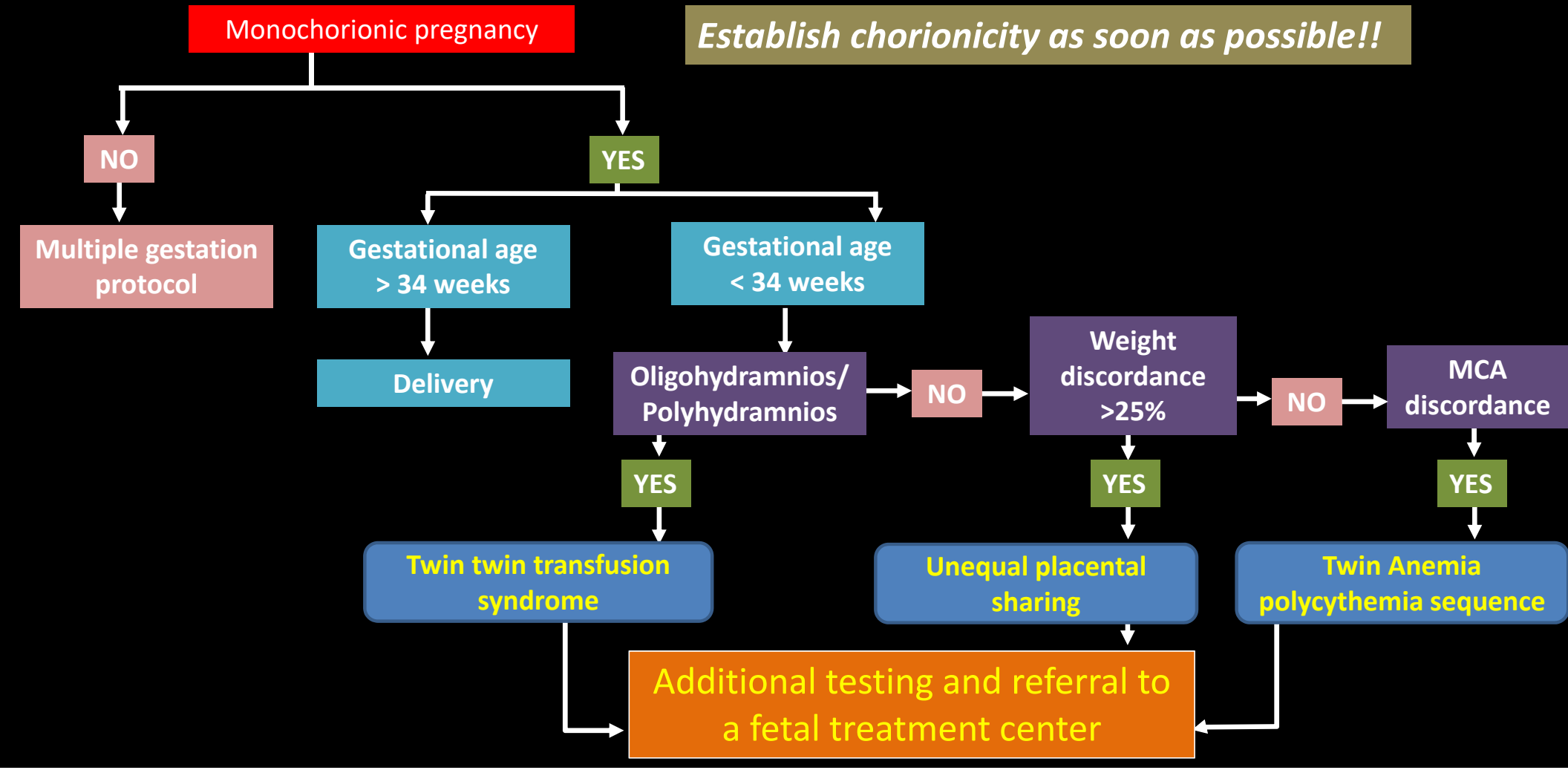

Thank you for viewing our presentation!

Email: priyanka.jha@ucsf.edu

References:

1. The North American Fetal Therapy Network consensus statement: prenatal surveillance of uncomplicated monochorionic gestations. Bahtiyar MO, Emery SP, Dashe JS, Wilkins-Haug LE, Johnson A, Paek BW, Moon-Grady AJ, Skupski DW, O'Brien BM, Harman CR, Simpson LL; North American Fetal Therapy Network. Obstet Gynecol. 2015 Jan;125(1):118-23. doi: 10.1097/AOG.0000000000000599.
2. The North American Fetal Therapy Network Consensus Statement: prenatal management of uncomplicated monochorionic gestations. Emery SP, Bahtiyar MO, Dashe JS, Wilkins-Haug LE, Johnson A, Paek BW, Moon-Grady AJ, Skupski DW, O'Brien BM, Harman CR, Simpson LL. Obstet Gynecol. 2015 May;125(5):1236-43. doi: 10.1097/AOG.0000000000000723.
3. The North American Fetal Therapy Network Consensus Statement: Management of Complicated Monochorionic Gestations.Emery SP, Bahtiyar MO, Moise KJ; North American Fetal Therapy Network. Obstet Gynecol. 2015 Sep;126(3):575-84. doi: 10.1097/AOG.0000000000000994.
4. Fetal growth restriction in twins. Townsend R, Khalil A. Best Pract Res Clin Obstet Gynaecol. 2018 May;49:79-88. doi: 10.1016/j.bpobgyn.2018.02.004.
5. Role of fetal inter-twin middle cerebral artery peak systolic velocity differences in predicting neonatal twin anemia-polycythemia sequence (TAPS). Tavares de Sousa M, Fonseca A, Hecher K. Ultrasound Obstet Gynecol. 2018 Sep 11.
6. Long-term outcomes for monochorionic twins after laser therapy in twin-to-twin transfusion syndrome. Hecher K, Gardiner HM, Diemert A, Bartmann P. Lancet Child Adolesc Health. 2018 Jul;2(7):525-535. doi: 10.1016/S2352-4642(18)30127-5. Epub 2018 May 30.
7. Stage I Twin-Twin Transfusion Syndrome: Outcomes of Expectant Management and Prognostic Features. Washburn EE, Sparks TN, Gosnell KA, Rand L, Gonzalez JM, Feldstein VA. Am J Perinatol. 2018 Feb 8.
8. Long-Term Neurodevelopmental Outcome of Monochorionic Twins after Laser Therapy or Umbilical Cord Occlusion for Twin-Twin Transfusion Syndrome. Schou KV, Lando AV, Ekelund CK, Jensen LN, Jørgensen C, Nørgaard LN, Rode L, Søgaard K, Tabor A, Sundberg K. Fetal Diagn Ther. 2018 Aug 27:1-8. doi: 10.1159/000491787.
9. Improved antenatal prediction of twin anemia-polycythemia sequence by delta middle cerebral artery peak systolic velocity: a new antenatal classification system. Tollenaar LSA, Lopriore E, Middeldorp JM, Haak MC, Klumper FJ, Oepkes D, Slaghekke F. Ultrasound Obstet Gynecol. 2018 Aug 20
10. Perinatal mortality, timing of delivery and prenatal management of monoamniotic twin pregnancies: systematic review and meta-analysis. D'Antonio F, Odibo A, Berghella V, Khalil A, Hack K, Saccone G, Prefumo F, Buca D, Liberati M, Pagani G, Acharya G. Ultrasound Obstet Gynecol. 2018 Aug 20.
11. Risk factors for fetal death after radiofrequency ablation for complicated monochorionic twin pregnancies. Sun L, Zou G, Yang Y, Zhou F, Tao D. Prenat Diagn. 2018 Jun;38(7):499-503.
12. Prevalence, antenatal management and perinatal outcomes of monochorionic monoamniotic twin pregnancies: a collaborative multicentre study in England, 2000-2013. Glinianaia SV, Rankin J, Khalil A, Binder J, Waring G, Sturgiss SN, Thilaganathan B, Hannon T. Ultrasound Obstet Gynecol. 2018
13. Sudden Fetal Hematologic Changes as a Complication of Amnioreduction in Twin-Twin Transfusion Syndrome. Kosinska-Kaczynska K, Lipa M, Szymusik I, Bomba-Opon D, Brawura-Biskupski-Samaha R, Kozlowski S, Tollenaar LSA, Oepkes D, Wielgos M, Lopriore E. Fetal Diagn Ther. 2018
14. Brain-injured Survivors of Monochorionic Twin Pregnancies Complicated by Single Intrauterine Death: MR Findings in a Multicenter Study. Conte G, Righini A, Griffiths PD, Rustico M, Lanna M, Mackie FL, Pinelli L, Prefumo F, Persico N, Igra MS, Parazzini C, Doneda C, Fichera A, Ambrosi C, Kilby M, Severino M, Triulzi F, Rossi A, Skipper N. Radiology. 2018 Aug;288(2):582-590.
15. Survival Rate without Brain Abnormalities on Postnatal Ultrasonography among Monochorionic Twins after Fetoscopic Laser Photocoagulation for Selective Intrauterine Growth Restriction with Concomitant Oligohydramnios. Ishii K, Wada S, Takano M, Nakata M, Murakoshi T, Sago H. Fetal Diagn Ther. 2018 Feb 20.